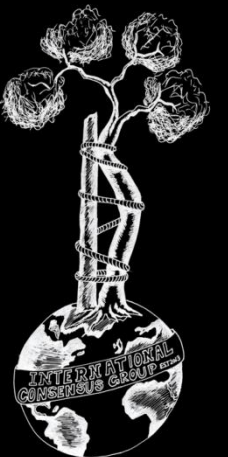
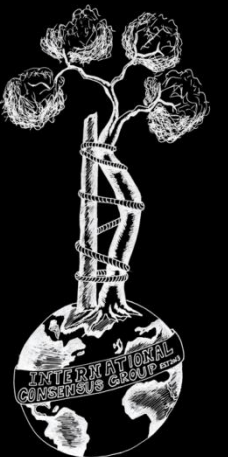


# ICM Oncology Consensus



# Prevention



# Onc-1 (Former Onc-1) Do we need to evaluate the gut and skin microbiome of patients after chemotherapy to assess the risk for potential infection after endoprosthetic reconstruction?

RESEARCHED BY:



Lor Randall  
MD, USA



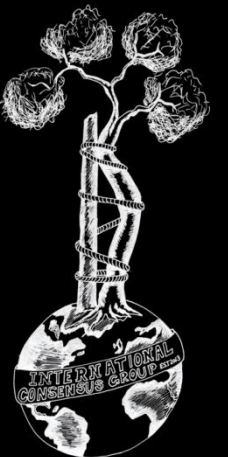
Brian Smith,  
USA



Karan  
Goswami  
MD, UK

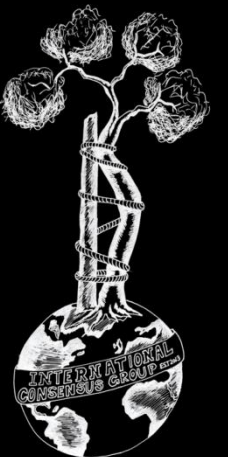


Panayiotis  
Papagelopoulos  
MD, Greece



# Literature:

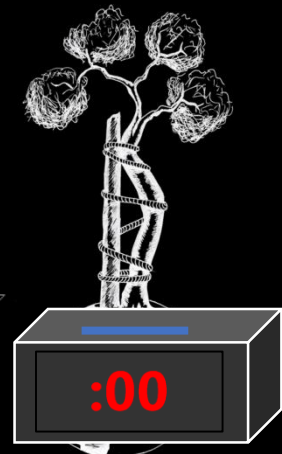
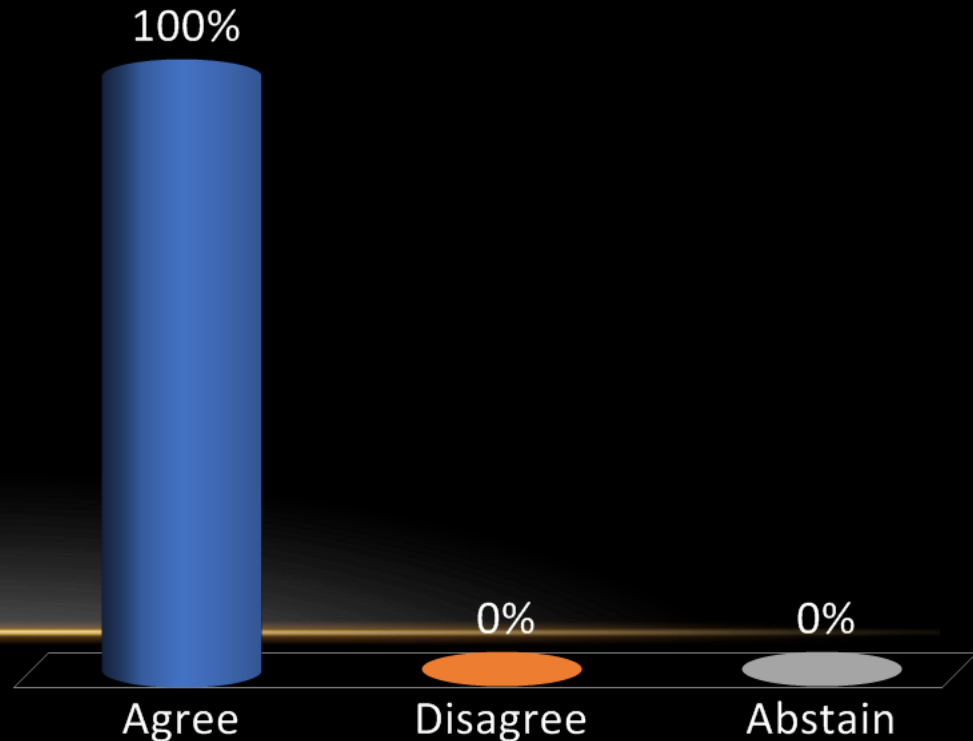
- **Meta-analysis 2, Prospective/Randomized 0, Retrospective 13**
- **Limited evidence demonstrating clarifying whether skin and gut microbiome testing would prove useful in risk stratification for infection following endoprosthetic reconstruction.**

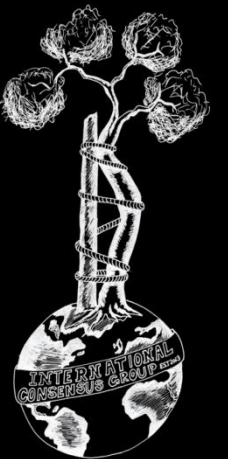


**Recommendation:** Unknown. While the effects of chemotherapy are known to influence skin/gut microbiome, there is no evidence in the literature to suggest that evaluation of the gut and/or skin microbiome following chemotherapy aids with risk stratification for potential infection in patients undergoing endoprosthetic limb salvage surgery.

**Level of Evidence: Consensus**

- A. Agree
- B. Disagree
- C. Abstain



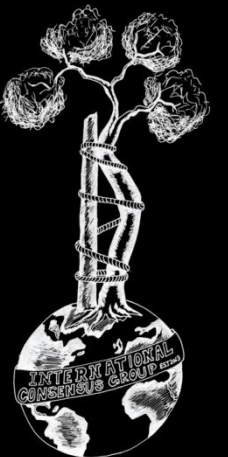


**Onc-2 (Former Onc-2)** Does the type of fixation (cemented vs. uncemented) of an oncologic endoprosthesis influence the incidence of subsequent SSI/PJI?

**RESEARCHED BY:**

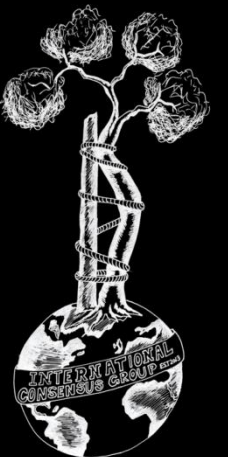


Richard O'Donnell MD, USA



# Literature:

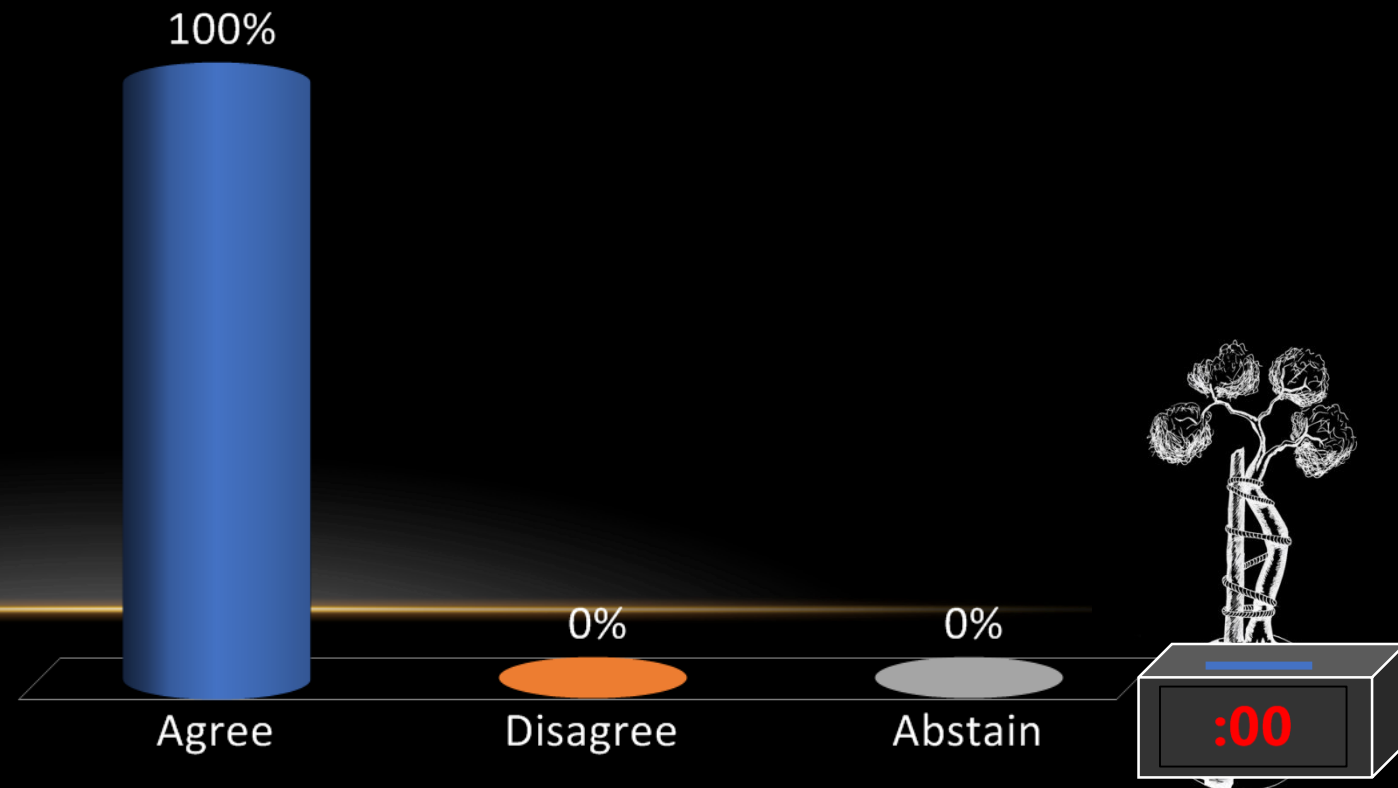
- **Meta-analysis 1, Prospective/Randomized 0, Retrospective 9**
- **Limited evidence demonstrating that the type of fixation (cemented vs. uncemented) influences the incidence of SSI/PJI**

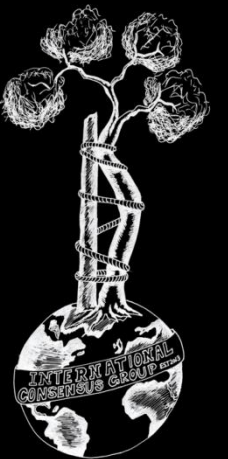


**Recommendation:** There is conflicting evidence surrounding this topic. Multiple studies have demonstrated superiority with cemented fixation of an oncologic endoprosthesis while others have suggested superiority with uncemented fixation. Therefore, the choice of the method of fixation should be made on the basis of all clinical indications, other than the influence of fixation on subsequent SSI/PJI.

**Level of Evidence: Limited**

- A. Agree
- B. Disagree
- C. Abstain





**Onc-3 (Former Onc-4)** Does the use of incise draping with antibacterial agents (iodine) influence the risk for subsequent SSI/PJI in patients undergoing musculoskeletal tumor surgeries?

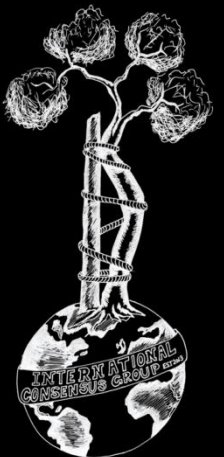
**RESEARCHED BY:**



Timothy Tan MD, USA

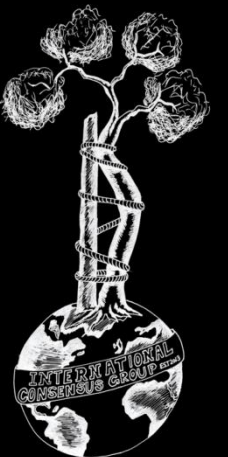


Takeshi Morii MD, Japan



# Literature:

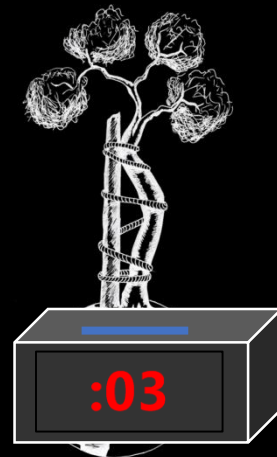
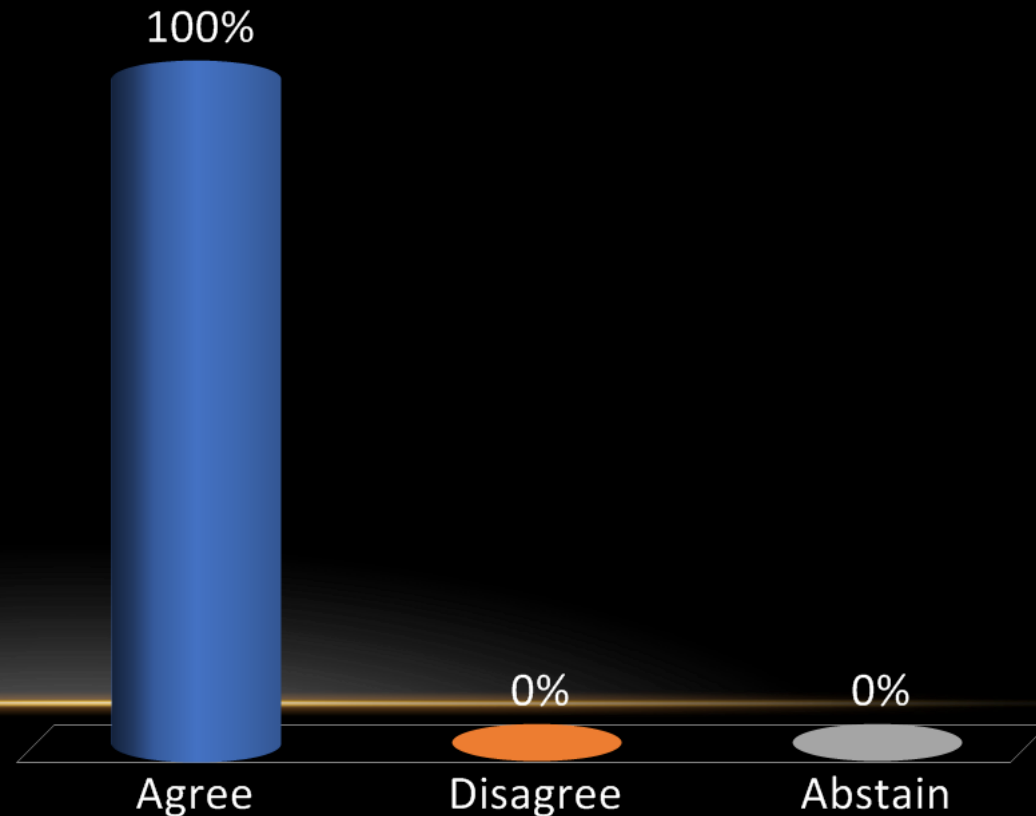
- **Meta-analysis 0, Prospective/Randomized 1, Retrospective 11**
- **Limited evidence demonstrating the beneficial effect of incise draping in reduction of surgical site infection, especially after tumor surgery.**

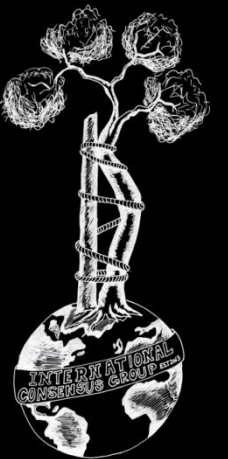


**Recommendation:** Unknown. There is some evidence that antimicrobial impregnated incise drapes result in a reduction in bacterial contamination at the surgical site. However, there are no studies demonstrating that they result in subsequent reduction in the incidence of surgical site infection (SSI) and/or periprosthetic joint infection (PJI) following musculoskeletal tumor surgery.

**Level of Evidence:** Limited

- A. Agree
- B. Disagree
- C. Abstain





**Onc-4 (Former Onc-6)** Does the use of soft tissue attachment meshes increase the risk for subsequent PJI in patients undergoing oncologic endoprosthetic reconstruction?

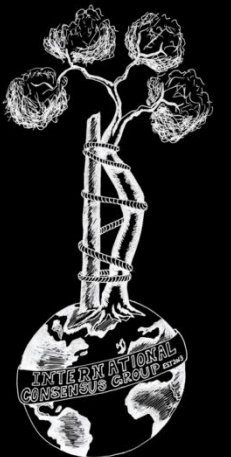**RESEARCHED BY:**



Aare MÄRTSON MD, Estonia

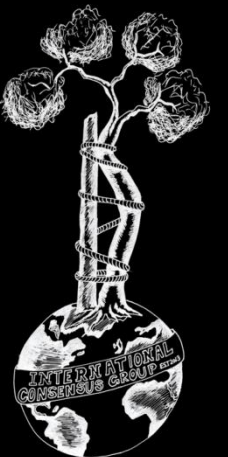


Irene Kalbian, USA



# Literature:

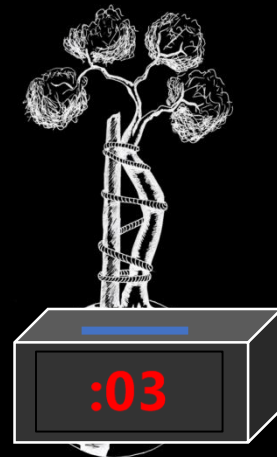
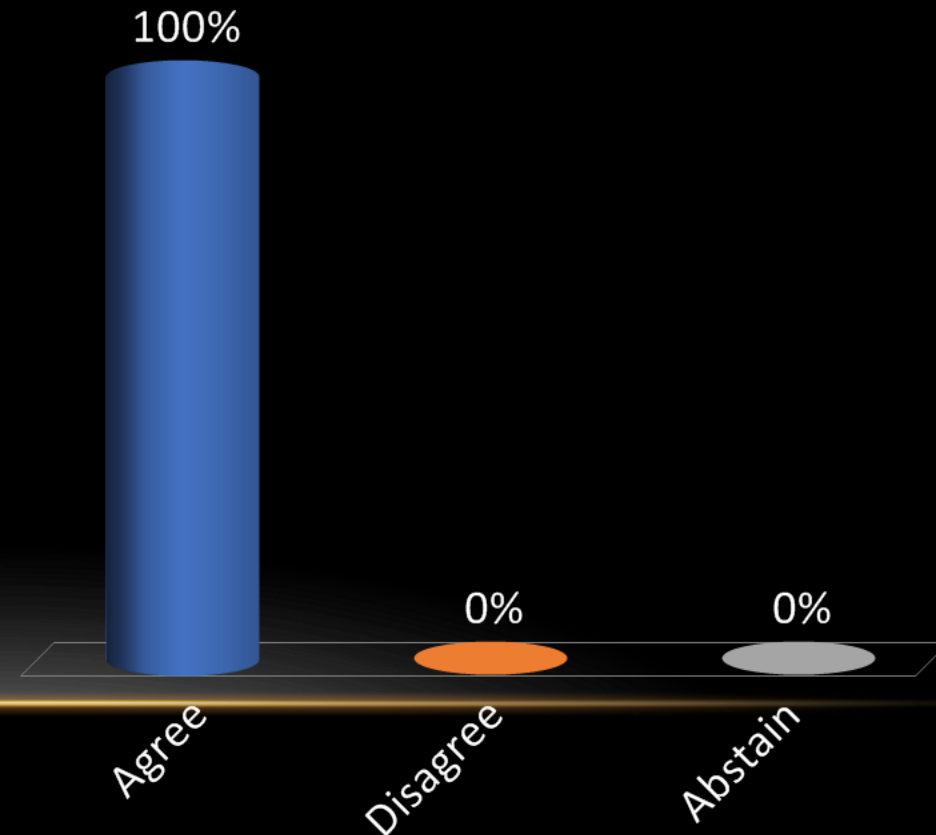
- **Meta-analysis 3, Prospective/Randomized 0, Retrospective 9**
- **Limited evidence suggesting little or no association between the use of mesh for soft tissue attachment with endoprosthetic reimplantation and development of subsequent PJI.**

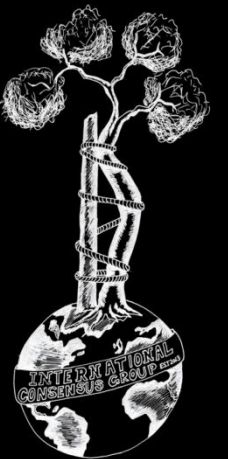


**Recommendation:** The current literature indicates that there is no increased risk of PJI in this patient population with the use of soft tissue attachment meshes. However, there are few studies directly comparing the use of mesh versus not using mesh in comparable tumors/surgical locations.

**Level of Evidence: Limited**

- A. Agree
- B. Disagree
- C. Abstain





**Onc-5 (Former Onc-10)** Is there a correlation between operative time and the risk of subsequent SSI/PJI in patients undergoing tumor resection and endoprosthetic reconstruction? If so, should postoperative prophylactic antibiotics be prolonged in these patients?


**RESEARCHED BY:**



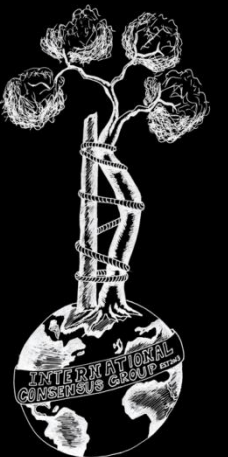
Christina Gutowski MD, USA



Michelle Ghert MD, Canada

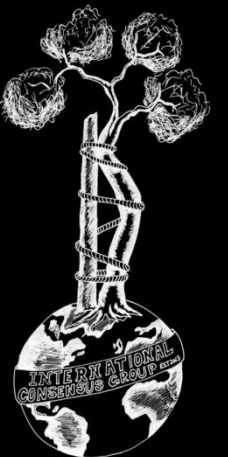


Qiaojie Wang MD, China



# Literature:

- **Meta-analysis 3, Prospective/Randomized 1, Retrospective 21**
- **Strong evidence demonstrating that prolonged operative time is associated with an increased risk for postoperative infection. Limited evidence suggesting evidence that a prolonged postoperative antibiotic regimen can mitigate this risk.**



### Recommendation:

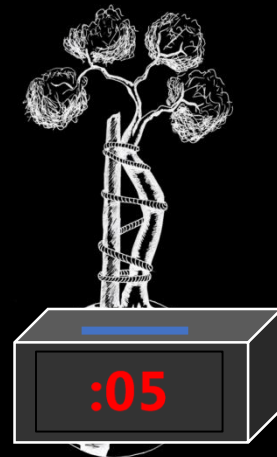
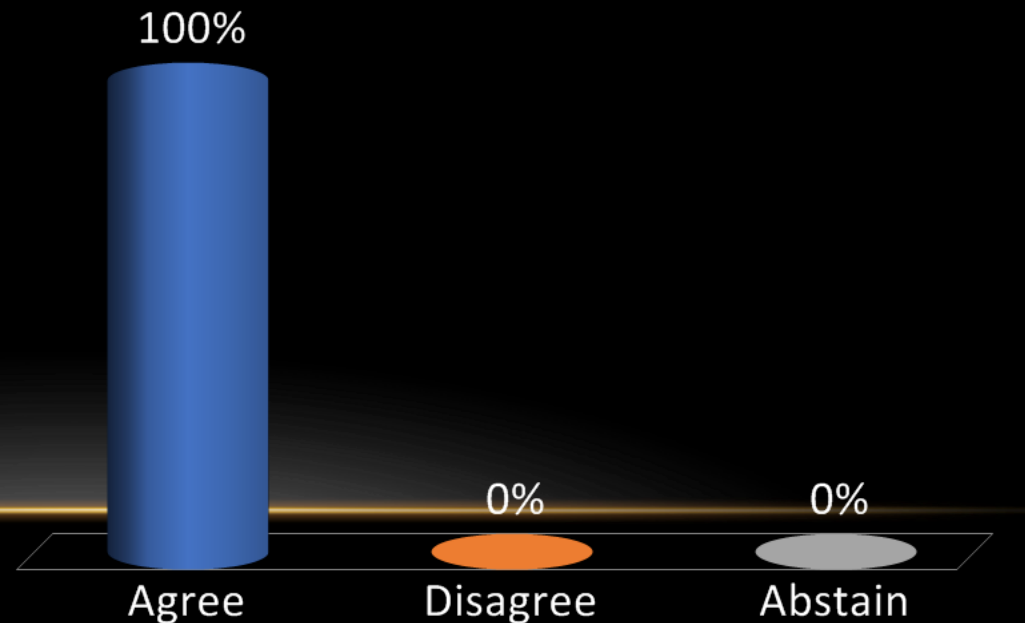
Based largely on arthroplasty literature, there is considerable evidence that prolonged operative time is associated with an increased risk for postoperative infection. If the duration of the procedure exceeds two half-lives of the prophylactic antimicrobial, intraoperative redosing is needed to ensure adequate serum and tissue concentrations of the antimicrobial.

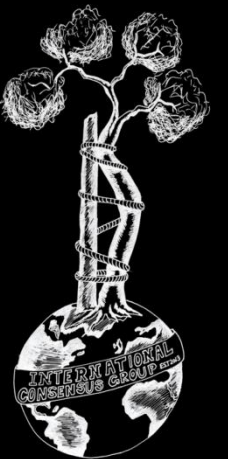
**Level of Evidence: Strong**

However, there is insufficient evidence to suggest that a prolonged postoperative antibiotic regimen can mitigate this risk. Therefore, there is no evidence to issue a recommendation regarding the duration of postoperative antibiotics in orthopaedic oncology.

**Level of Evidence: Moderate**

- A. Agree
- B. Disagree
- C. Abstain





**Onc-6 (Former Onc-12)** Is there an increased risk for subsequent SSI/PJI when a drainage tube is used in musculoskeletal tumor surgery?

**RESEARCHED BY:**



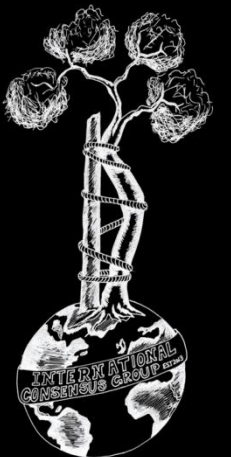
Aare Märtson MD, Estonia



Oscar Ares MD, Spain

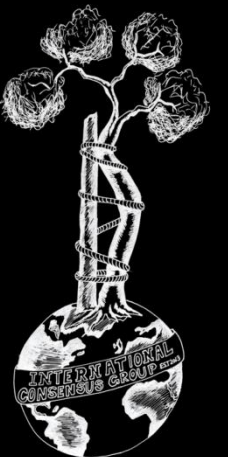


Jacek Markuszewski MD, Poland



# Literature:

- **Meta-analysis 2, Prospective/Randomized 1, Retrospective 8**
- **Meta-analyses showed a tendency towards a beneficial effect of not using a wound drain with regard to a reduced risk of wound infections with no statistical significance.**
- **Limited evidence demonstrating whether drainage tubes increase the risk of PJI/SSI in musculoskeletal tumor surgery.**

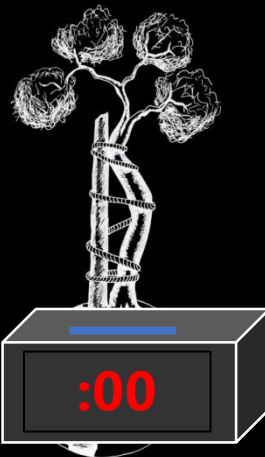
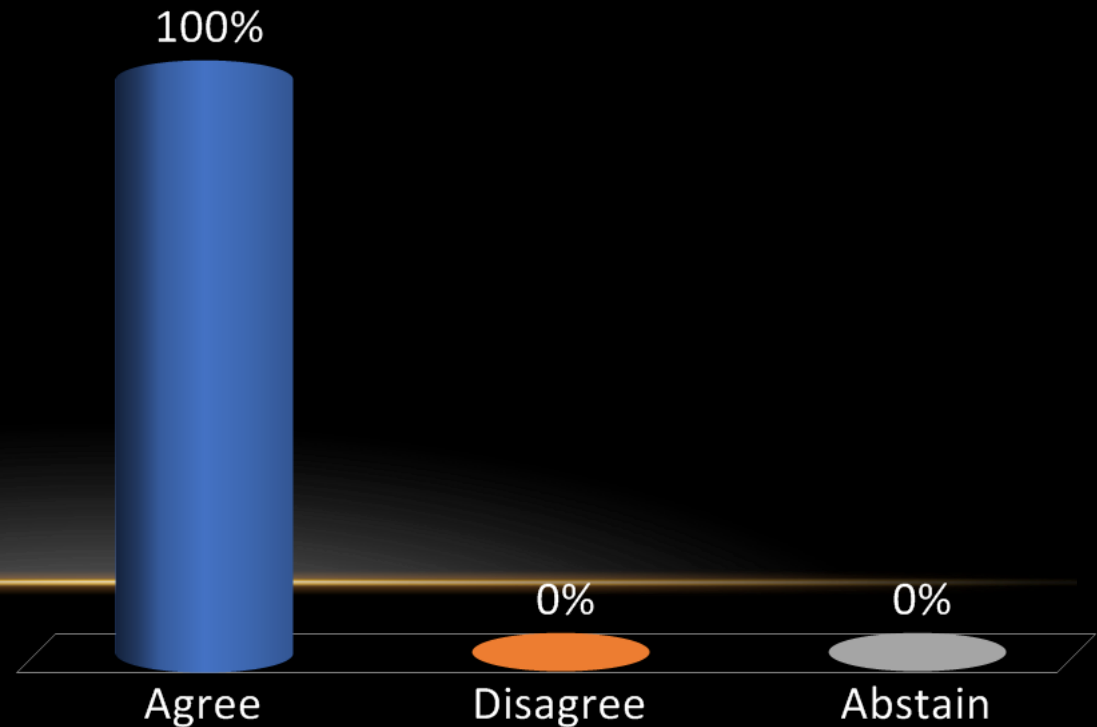


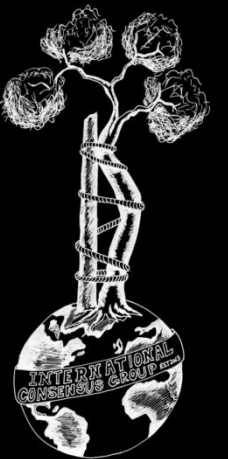
**Recommendation:** Unknown. There is no evidence linking the use of surgical drains and increased risk of SSI/PJI following musculoskeletal tumor surgery.

If used, surgical drains should be continuously monitored and removed immediately once output has decreased adequately per clinical judgement.

**Level of Evidence: Limited**

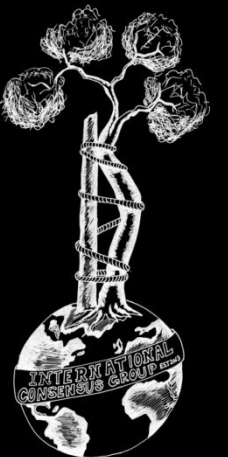

- A. Agree
- B. Disagree
- C. Abstain





**Onc-7 (Former Onc-13)** Should an absolute neutrophil count of  $>1000/\text{mm}^3$  be the minimum for patients undergoing limb salvage surgery after receiving chemotherapy?

**RESEARCHED BY:**



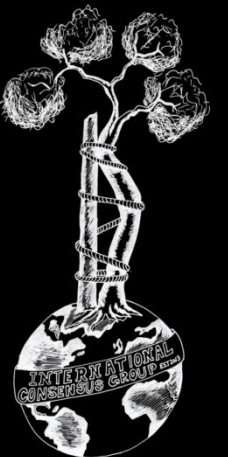
Andreas Mavrogenis MD, Greece

Takeshi Morii MD, Japan

Jorge Manrique MD, Colombia

# Literature:

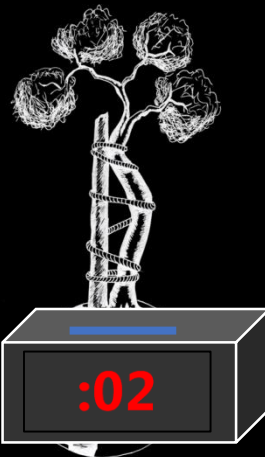
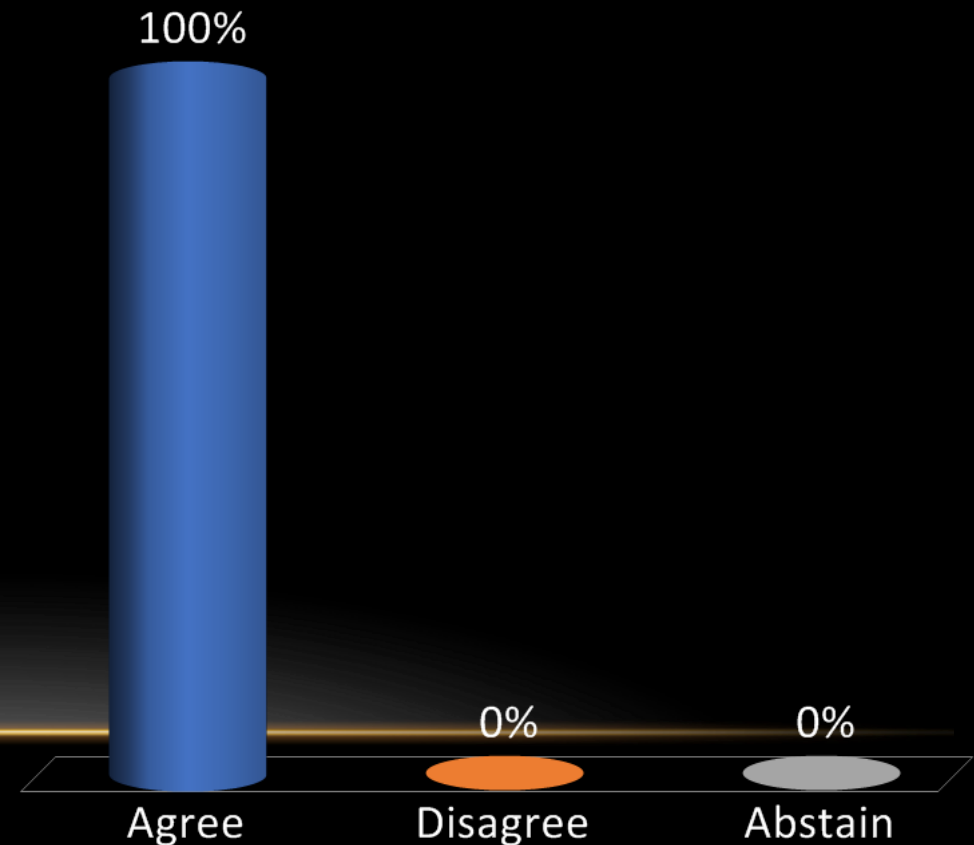
- **Meta-analysis 1, Prospective/Randomized 6, Retrospective 25**
- Given the available literature, we consider that patients with an ANC below 1000/mm<sup>3</sup>, either from the chemotherapy or the solid tumor itself, should not undergo limb salvage surgery until ANC is above 1000/mm<sup>3</sup> and possibly above 1500/mm<sup>3</sup>.

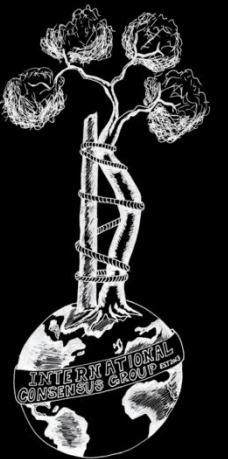


**Recommendation:** Yes. It is unsafe to perform limb salvage surgery for patients with an absolute neutrophil count (ANC)  $<1,000/\text{mm}^3$  after receiving chemotherapy.

**Level of Evidence: Consensus**

- A. Agree
- B. Disagree
- C. Abstain





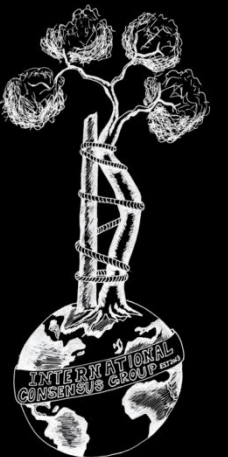
**Onc-8 (Former Onc-14)** Should endoprostheses and/or allograft bone be soaked in antibiotic solution or antiseptic solutions prior to implantation in patients?

**RESEARCHED BY:**



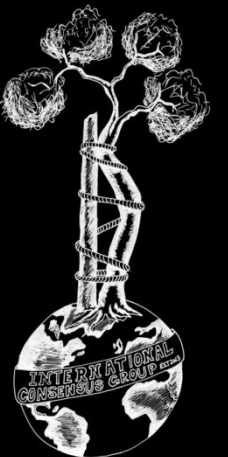
Lor Randall MD, USA

Antonious Papadopoulos MD, Greece



# Literature:

- **Meta-analysis 0, Prospective/Randomized 0, Retrospective 17**
- **Limited clinical studies- there are no randomized controlled trials or systematic reviews that have evaluated soaking endoprosthesis or allograft bone in antibiotic or antiseptic solutions before implantation for the prevention of surgical site infections**

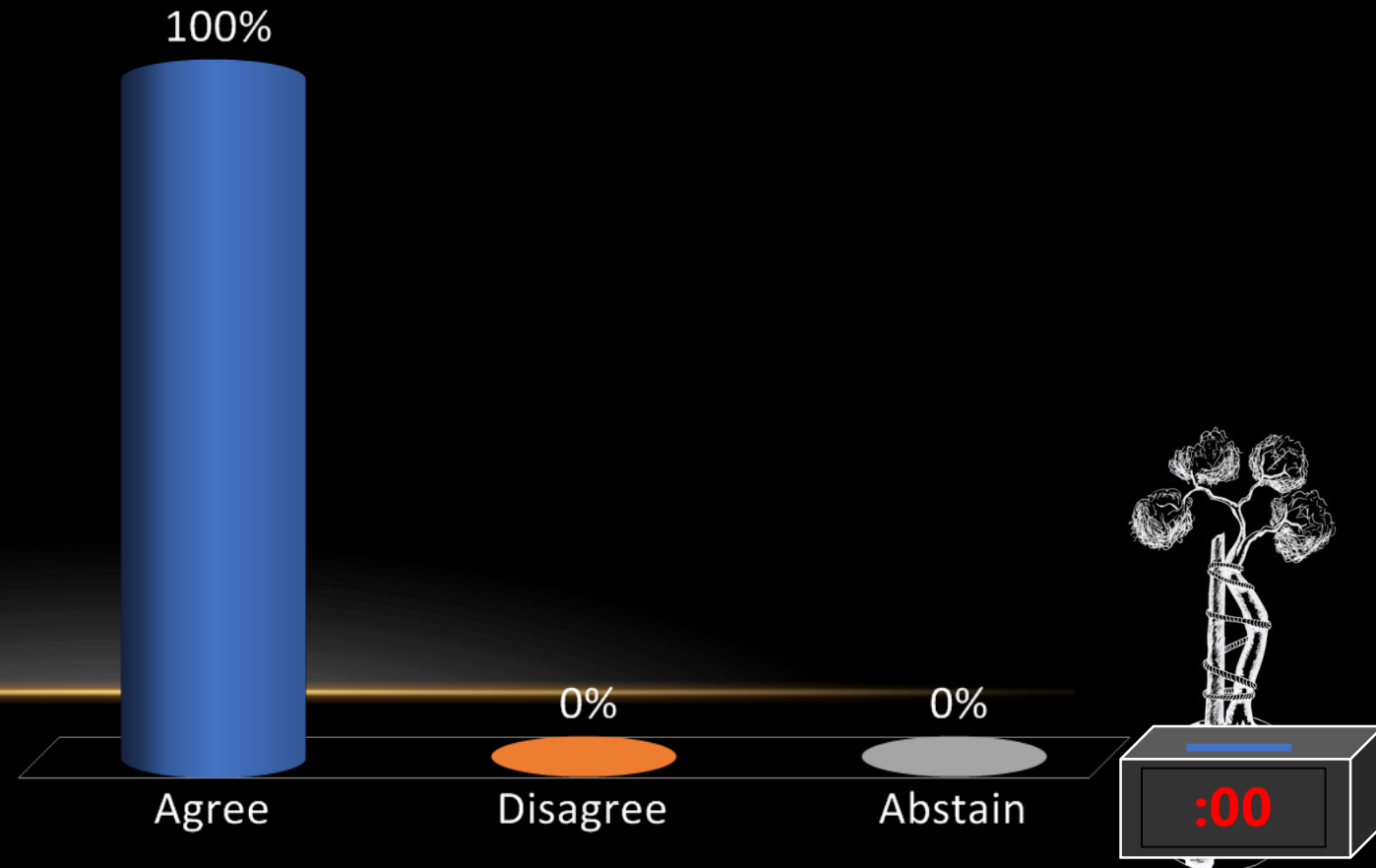


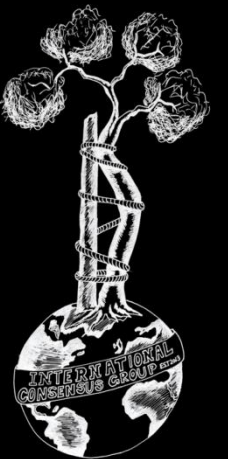
**Recommendation:** Unknown. There is no evidence to suggest that the use of a pre-implantation antibiotic or antiseptic soak of an endoprosthesis would reduce the rate of SSI/PJI but may be considered.

For massive allografts, the local bone bank protocol should be followed.

**Level of Evidence: Consensus**

- A. Agree
- B. Disagree
- C. Abstain





**Onc-9 (Former Onc-15)** Should factors like preoperative radiation, soft tissue vs. bone resection, presence of metal vs. structural allograft, and other factors influence the dose and duration of antibiotic prophylaxis?

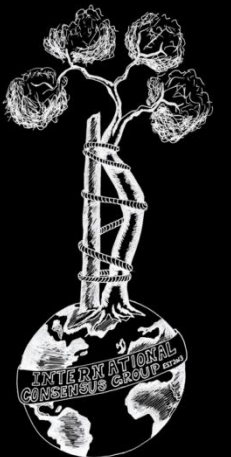
**RESEARCHED BY:**



Rodolfo Capanna MD, Italy

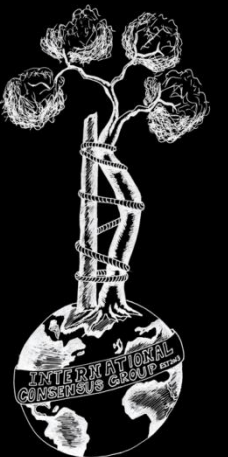


Ivan Bohacek MD, Croatia



# Literature:

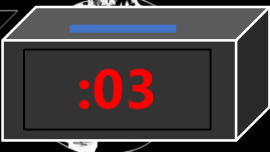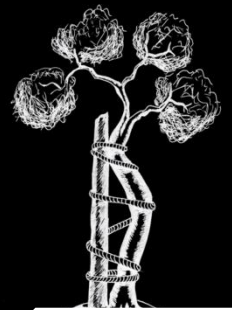
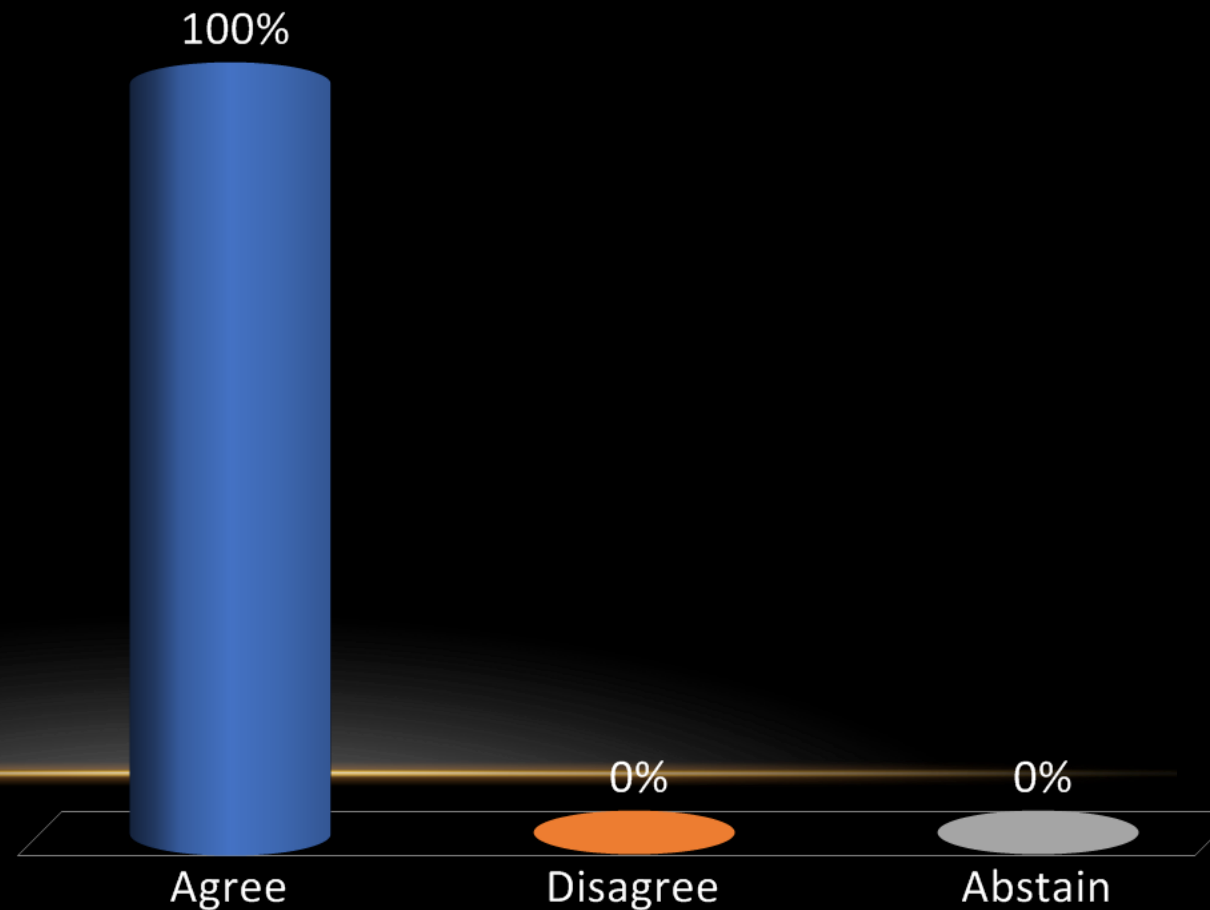
- **Meta-analysis 1, Prospective/Randomized 2, Retrospective 24**
- **Limited data on prophylactic antibiotic regimes. High quality, randomized controlled trials are needed for oncologic endoprosthesis or bulk bone allograft reconstructions in tumor orthopedic surgery.**

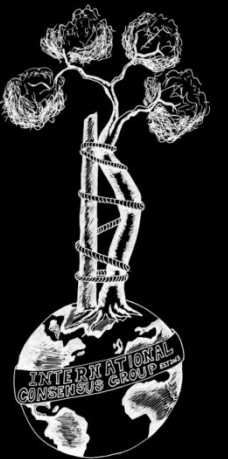


**Recommendation:** Unknown. Evidence and guidelines directing the prescription of prophylactic antibiotic regimens in musculoskeletal tumor surgery are lacking. Although long-term antibiotic prophylaxis may decrease the risk of deep infection, there is no evidence to recommend its routine use but studies are ongoing.

**Level of Evidence: Limited**

- A. Agree
- B. Disagree
- C. Abstain



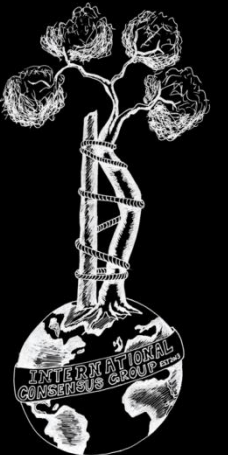


**Onc-10 (Former Onc-18)** Should patients with an oncologic endoprosthesis in place receive antibiotic prophylaxis during dental procedures?

**RESEARCHED BY:**

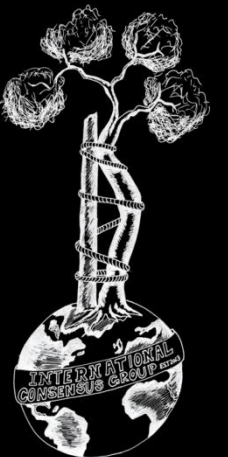


Mitchell Schwaber MD, Israel



# Literature:

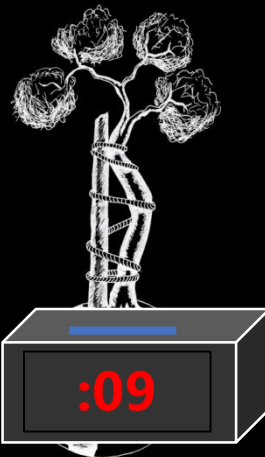
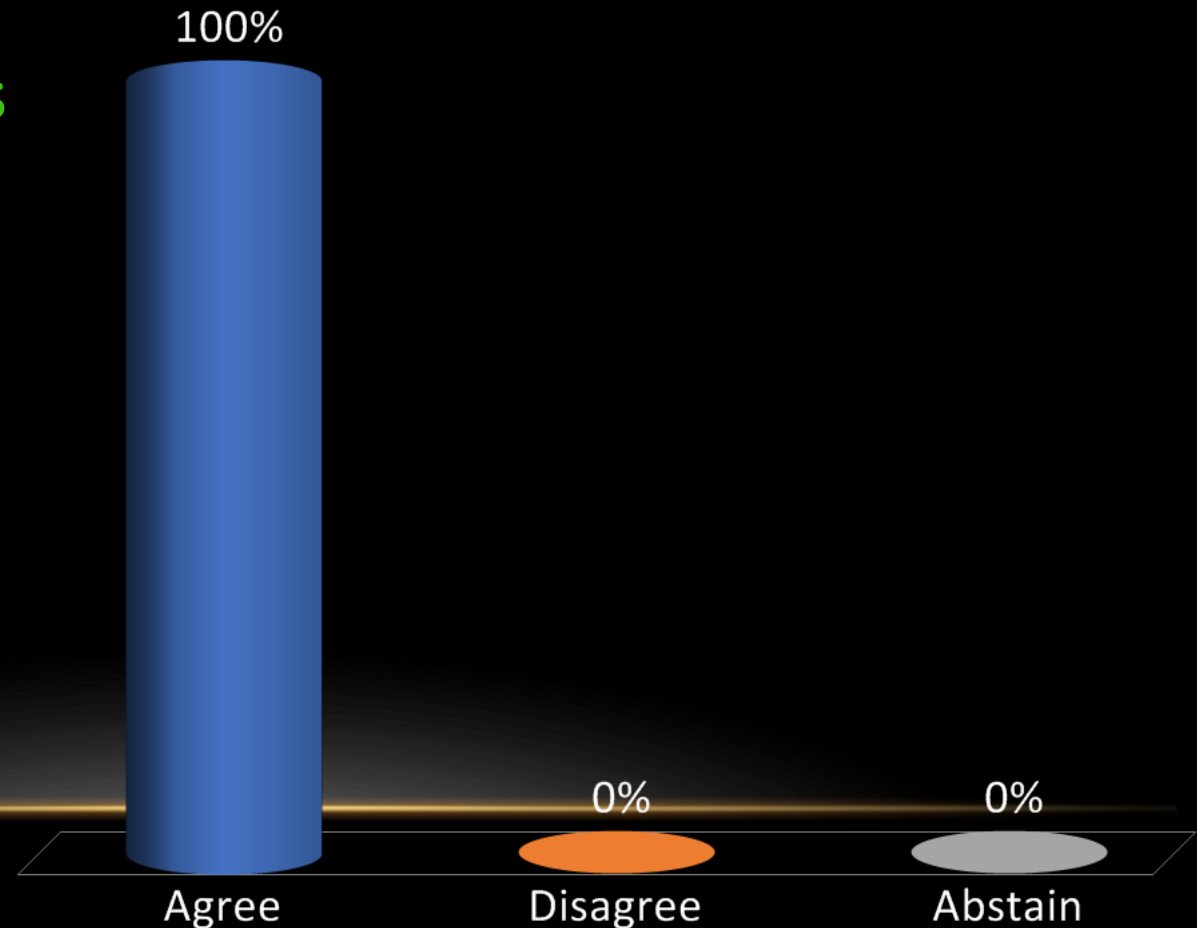
- **Meta-analysis 3, Prospective/Randomized 0, Retrospective 4**
- **There are no studies of the association between dental procedures and prosthetic joint infection (PJI) conducted specifically in patients with an oncologic endoprosthesis.**

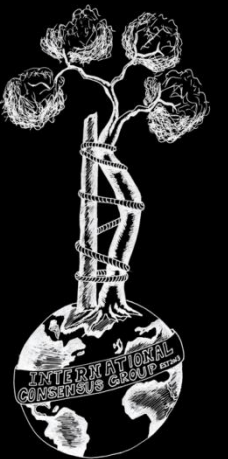


**Recommendation:** Unknown. There are no studies of the association between dental procedures and prosthetic joint infection conducted specifically in patients with an oncologic endoprosthesis.

**Level of Evidence: Consensus**

- A. Agree
- B. Disagree
- C. Abstain



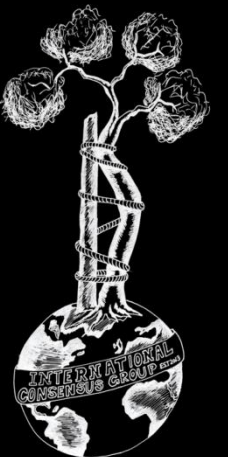


**Onc-11 (Former Onc-19)** Should prophylactic antibiotics be started in patients with an oncologic endoprosthesis who develop neutropenia secondary to postoperative chemotherapy?

**RESEARCHED BY:**

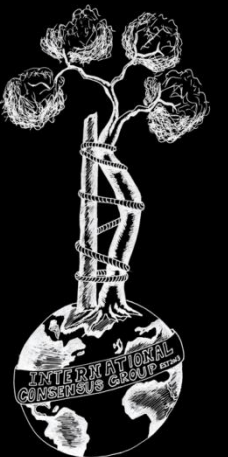


Mitchell Schwaber MD, Israel



# Literature:

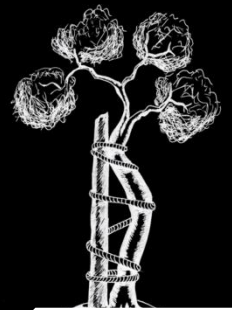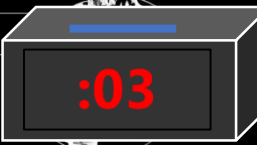
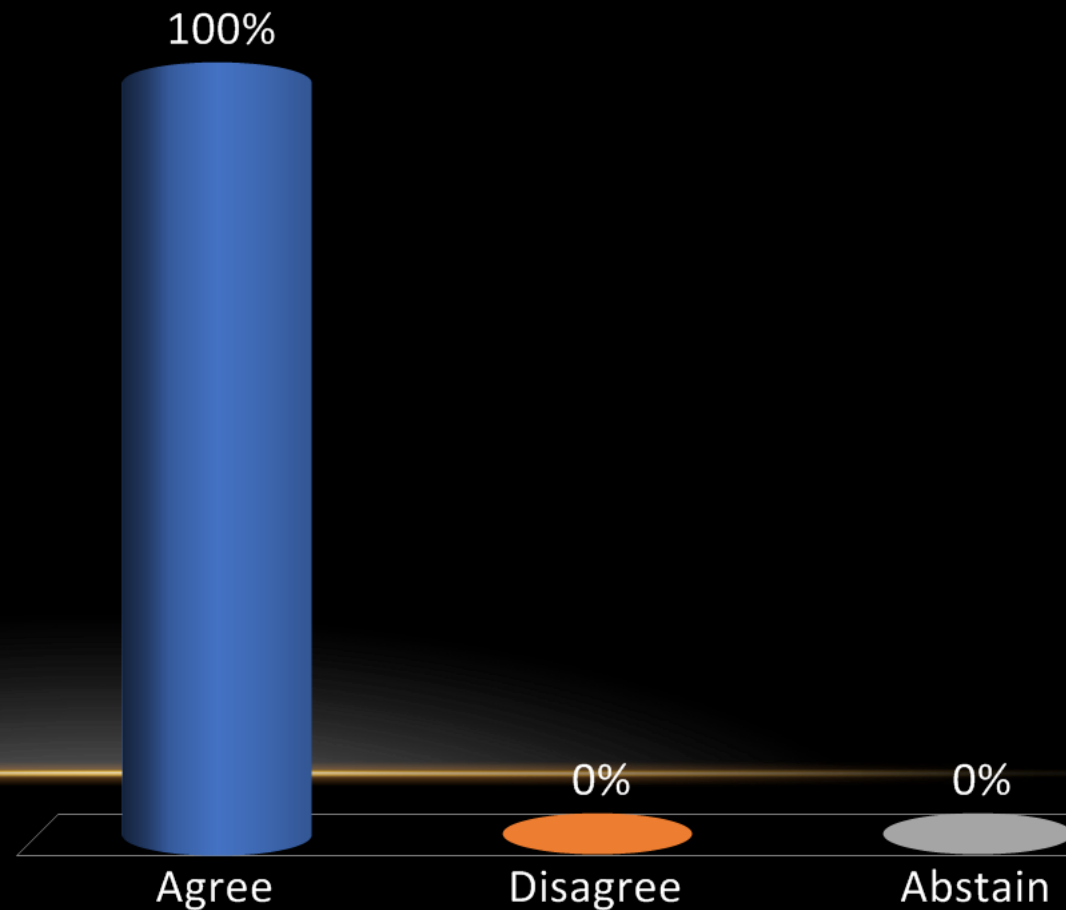
- **Meta-analysis 0, Prospective/Randomized 0, Retrospective 14**
- **Given the evidence to date, patients with an oncologic endoprosthesis should not routinely receive antibiotic prophylaxis during neutropenic episodes.**

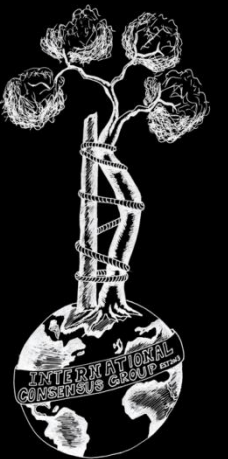


**Recommendation:** Not routinely. Evidence-based guidelines recommend the routine use of prophylactic antibiotics only for high-risk patients with chemotherapy-induced neutropenia. There are no specific guidelines for oncologic reconstructions.

**Level of Evidence: Consensus**

- A. Agree
- B. Disagree
- C. Abstain





**Onc-12 (Former Onc-21)** Should the serum white cell count be taken into account prior to endoprosthetic reconstruction in patients who have undergone recent chemotherapy?

**RESEARCHED BY:**



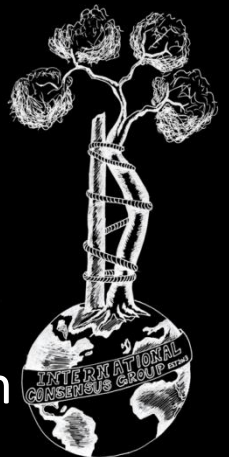
Michel van de Sande MD, Netherlands



Hiroyuki Tsuchiya MD, Japan

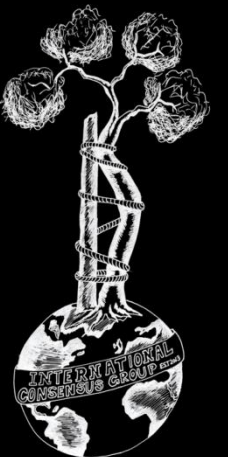


Daisuke Inoue MD, Japan



# Literature:

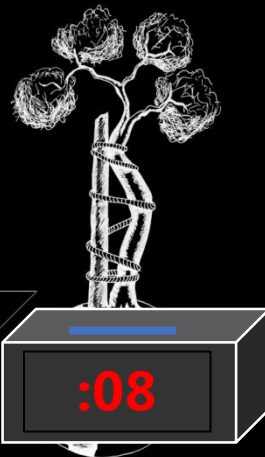
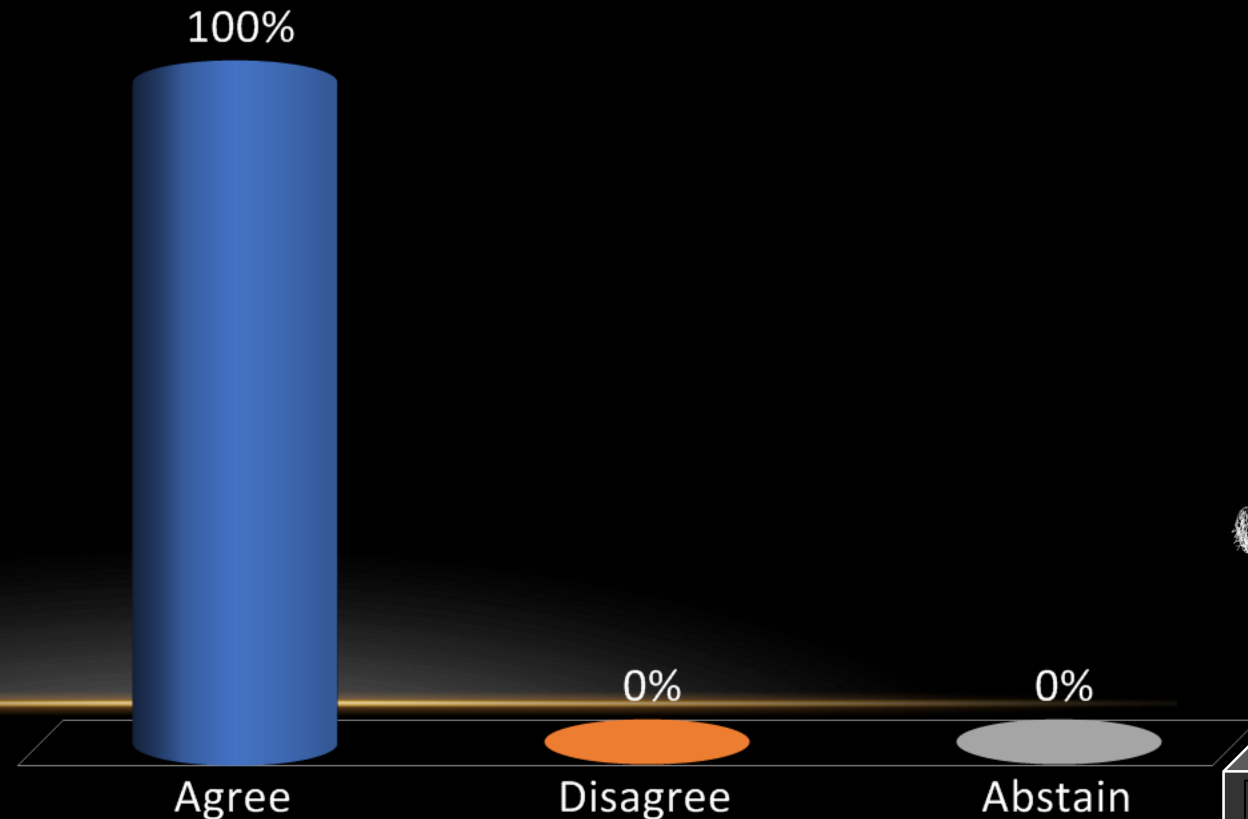
- **Meta-analysis 2, Prospective/Randomized 0, Retrospective 14**
- **Literature does not show any significant differences between the infection rates between patients who are undergoing chemotherapy and those who are not receiving it, it makes sense to determine the WBC number as an additional diagnostical tool.**

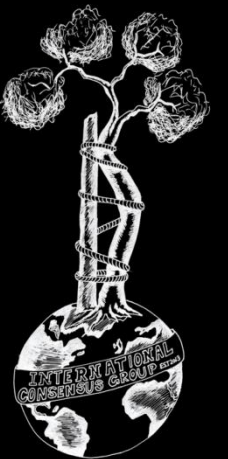


**Recommendation:** The association between chemotherapy and infection following endoprosthetic reconstruction remains controversial. However, in a multifactorial decision making process, there may be some benefit in accounting for the serum white blood cell (WBC) count prior to endoprosthetic reconstruction.

**Level of Evidence: Limited**

- A. Agree
- B. Disagree
- C. Abstain



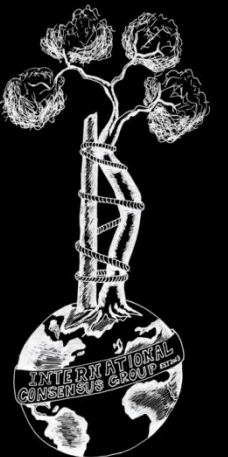


**Onc-13 (Former Onc-22)** Should a coated prosthesis (silver/iodine) be used for reconstruction of patients undergoing primary bone tumour resection?

**RESEARCHED BY:**

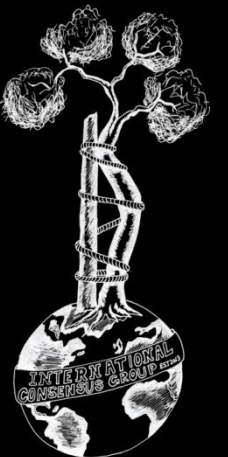


Muhammad Siddiqi MD, Pakistan



# Literature:

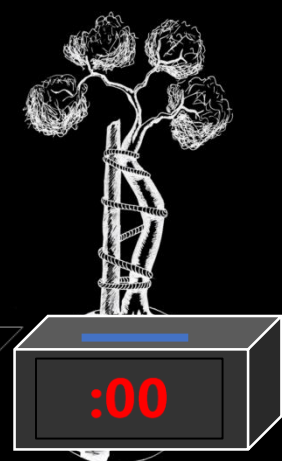
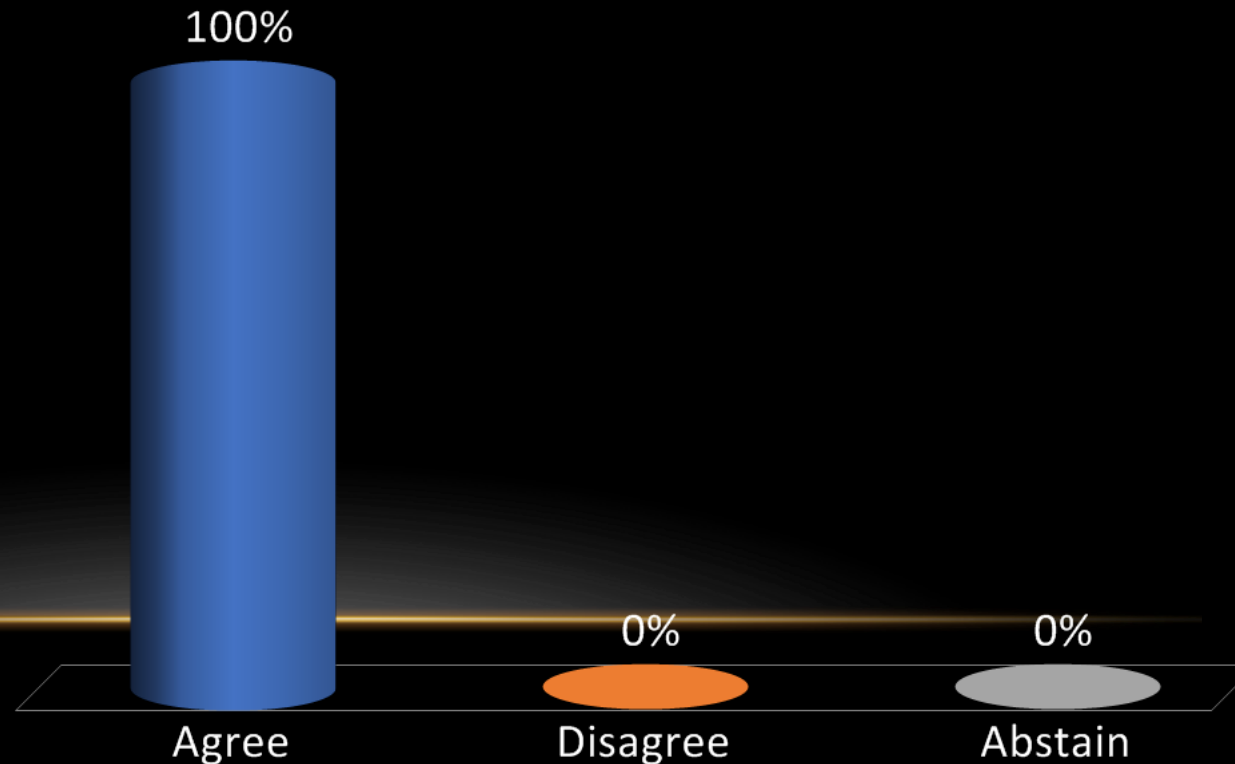
- **Meta-analysis 0, Prospective/Randomized 0, Retrospective 15**
- **Moderate evidence from literature suggesting that coated prostheses can be used in patients undergoing primary bone tumour resection**

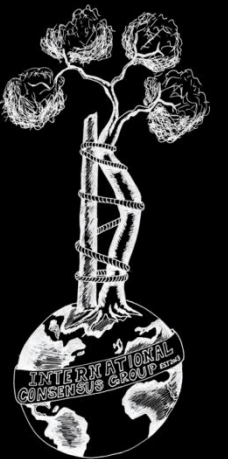


**Recommendation:** Silver coating and iodine coating of a prosthesis may decrease the risk of infection after reconstruction following primary tumor resection.

**Level of Evidence: Moderate**

- A. Agree
- B. Disagree
- C. Abstain





**Onc-14 (Former Onc-23)** What are the significant risk factors for SSI/PJI of an oncologic endoprosthesis following resection of a malignant bone tumor?

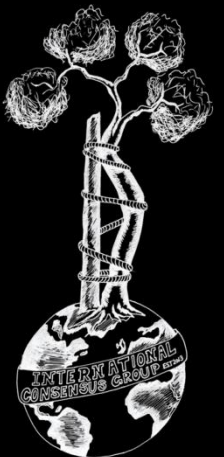
**RESEARCHED BY:**



Rodolfo Capanna MD, Italy

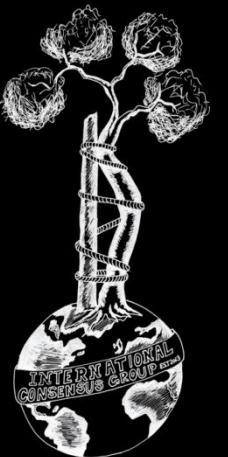


Ivan Bohacek MD, Estonia



# Literature:

- **Meta-analysis 4, Prospective/Randomized 0, Retrospective 13**
- **Moderate evidence from literature suggesting multiple risk factors for SSI/PJI of an oncologic endoprosthesis following resection of a malignant bone tumor including patient-, disease-, and procedure-related risk factors.**



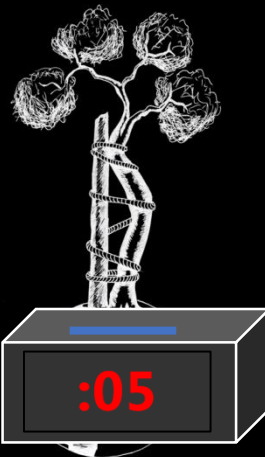
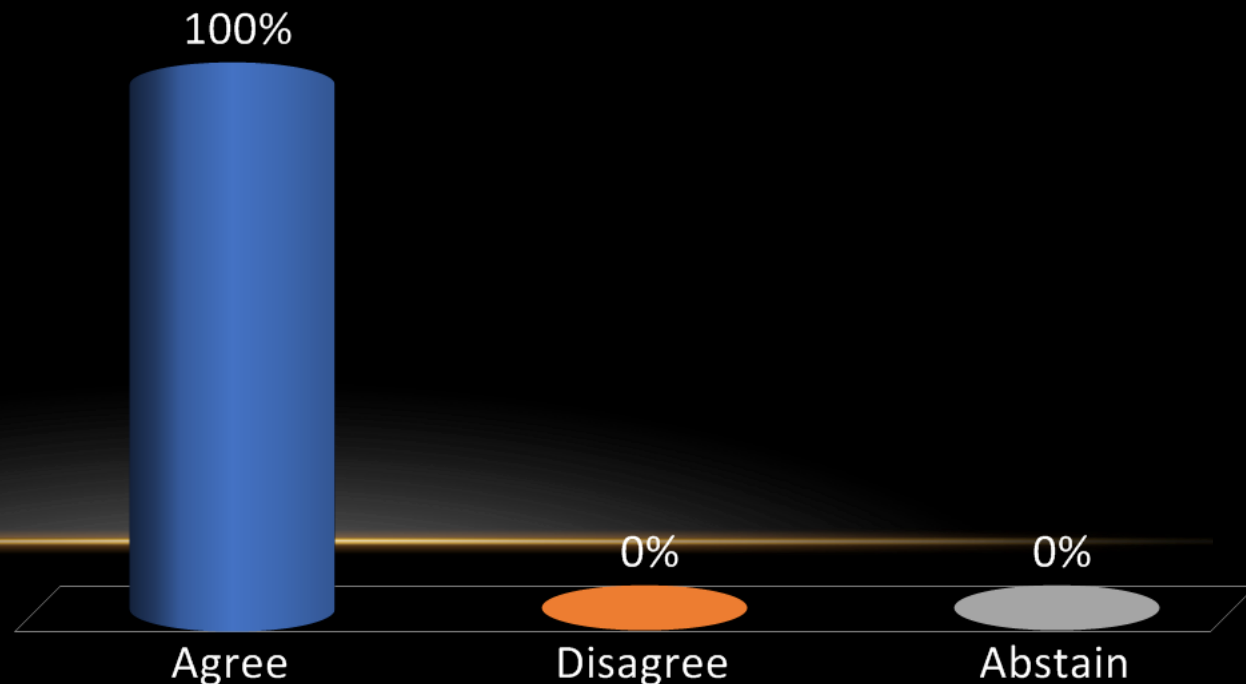
## Recommendation:

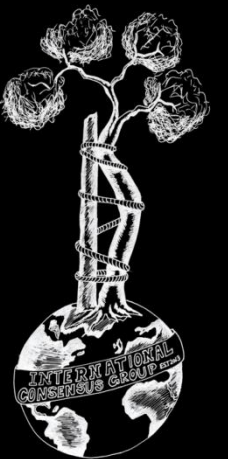
Significant risk factors include:

- Patient risk factors include abnormal body mass index, presence of comorbidities, coexistence of SSI or skin necrosis and low pre-op hemoglobin or albumin levels.
- Disease risk factors include lesion localization in proximal tibia, pelvis, and lesion extending to pelvis from proximal femur.
- Procedure risk factors include preop hospitalization > 48 hours, resection of greater than approximately 1/3 of the proximal tibia, resection of 3 or 4 heads of the quadriceps muscle in distal femoral lesions compared to 1 or 2 heads, increased surgical time, admission to ICU, increased postoperative blood transfusion requirement, postoperative hematoma, and the need for additional surgical procedures.

Level of Evidence: Moderate

- A. Agree
- B. Disagree
- C. Abstain



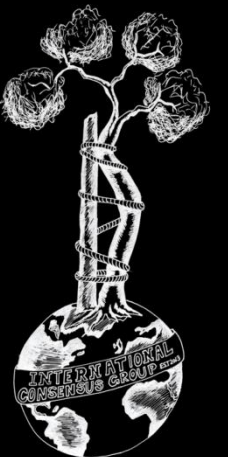


**Onc-15 (Former Onc-28)** What is the optimal local antimicrobial delivery strategy during limb salvage: antibiotic cement, silver-coated implant, iodine-coated implant, topical vancomycin powder, injection of antibiotics via drain tubing, other?

**RESEARCHED BY:**

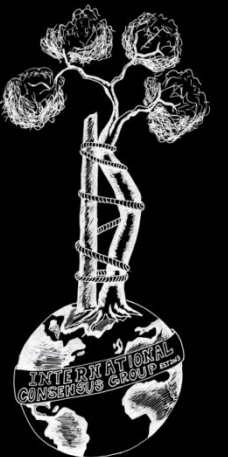


Mitchell Schwaber MD, Israel



# Literature:

- **Meta-analysis 1, Prospective/Randomized 0, Retrospective 13**
- **Limited evidence comparing local antimicrobial strategies during limb salvage procedures.**

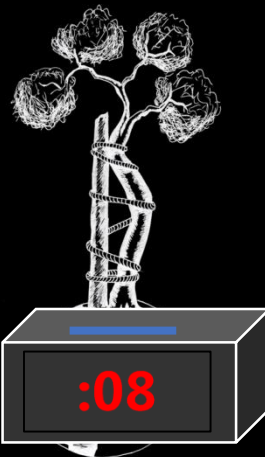
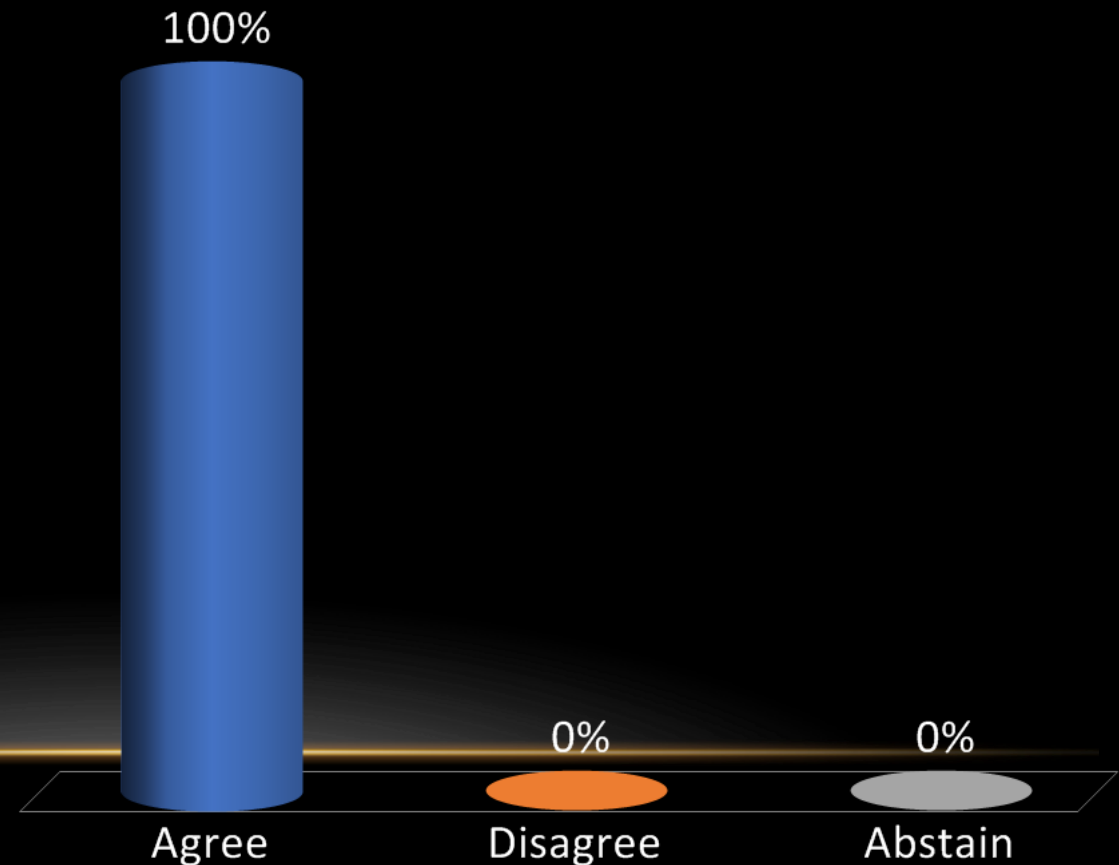


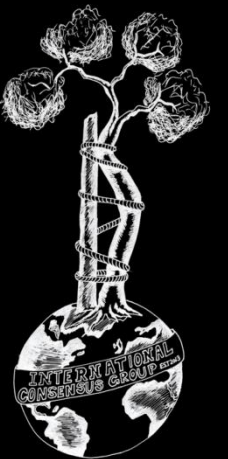
## Recommendation:

Unknown. No direct comparison has been made of different antimicrobial delivery strategies in oncological patients undergoing limb salvage procedures.

## Level of Evidence: Limited

- A. Agree
- B. Disagree
- C. Abstain





# Onc-16 (Former Onc-29) What metrics should be used to determine the optimal timing of reimplantation for patients with a resected oncologic endoprosthesis?

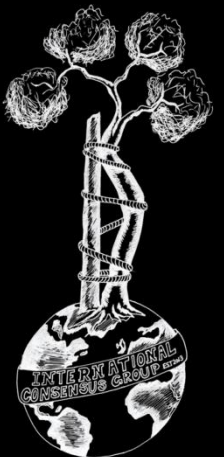
## RESEARCHED BY:



Roberto Velez MD, Spain

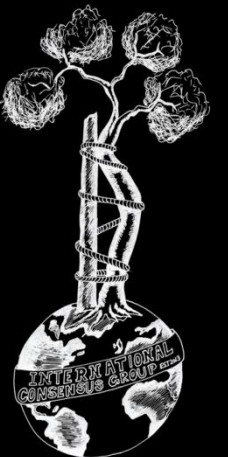


Michelle Ghert MD, Canada



# Literature:

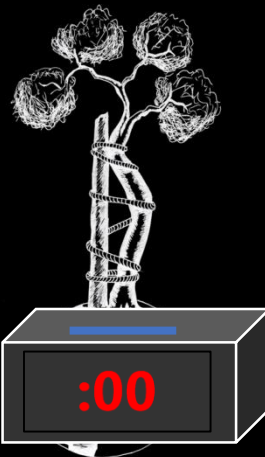
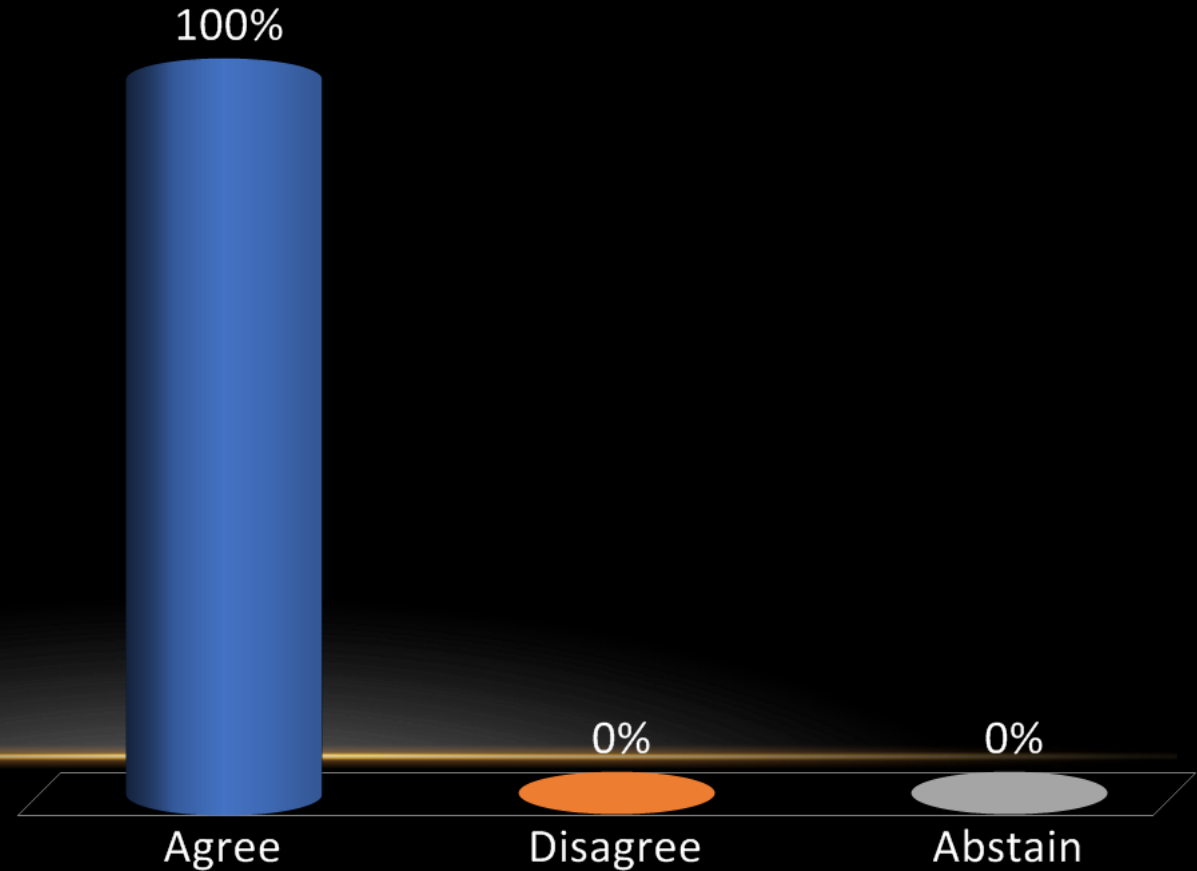
- **Meta-analysis 0, Prospective/Randomized 0, Retrospective 13**
- **Despite the lack of higher quality literature, there has been consistent support by several retrospective studies for using sterile periprosthetic cavity aspirates as a clinical metric to indicate optimal timing for oncological endoprosthesis reimplantation.**

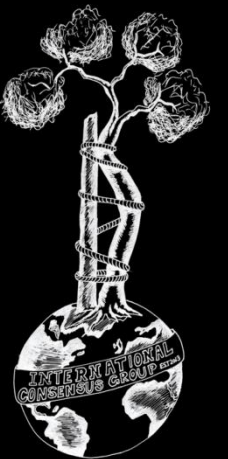


**Recommendation:** Prior to reimplantation of an oncologic endoprosthesis after a previous resection, surgeons must ensure that the infection has been eradicated from the surgical bed - using the same criteria used for revision arthroplasty for infection.

**Level of Evidence: Moderate**

- A. Agree
- B. Disagree
- C. Abstain





**Onc-17 (Former Onc-30)** What should be the time delay between preoperative chemo/radiotherapy and a surgical tumor resection in order to minimize incidence of SSI/PJI?

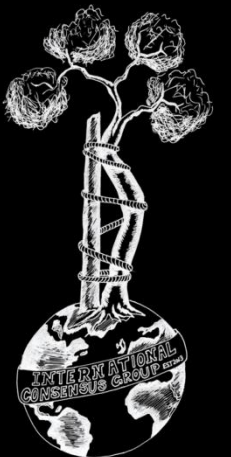
**RESEARCHED BY:**



German Farfalli MD, Argentina

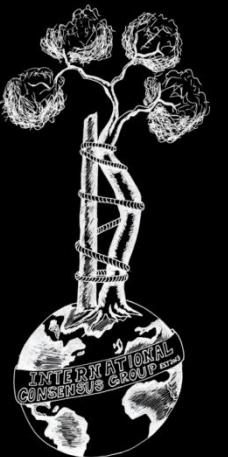


Peter Choong MD, Australia



# Literature:

- **Meta-analysis 5, Prospective/Randomized 2, Retrospective 17**
- There is strong evidence supporting the association between pre-op chemo/radiotherapy on post-op SSIs. However, there are a few papers examining the time delay. Two papers show no significant difference between surgical timing post radiotherapy/chemotherapy with respect to wound complications, however there was a trend towards higher wound complications rates in <3 weeks and > 6 weeks.

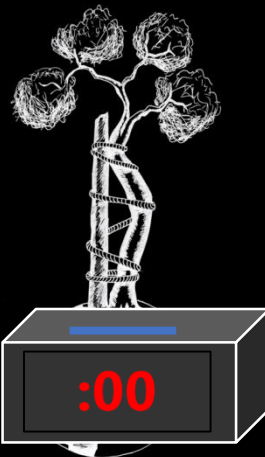
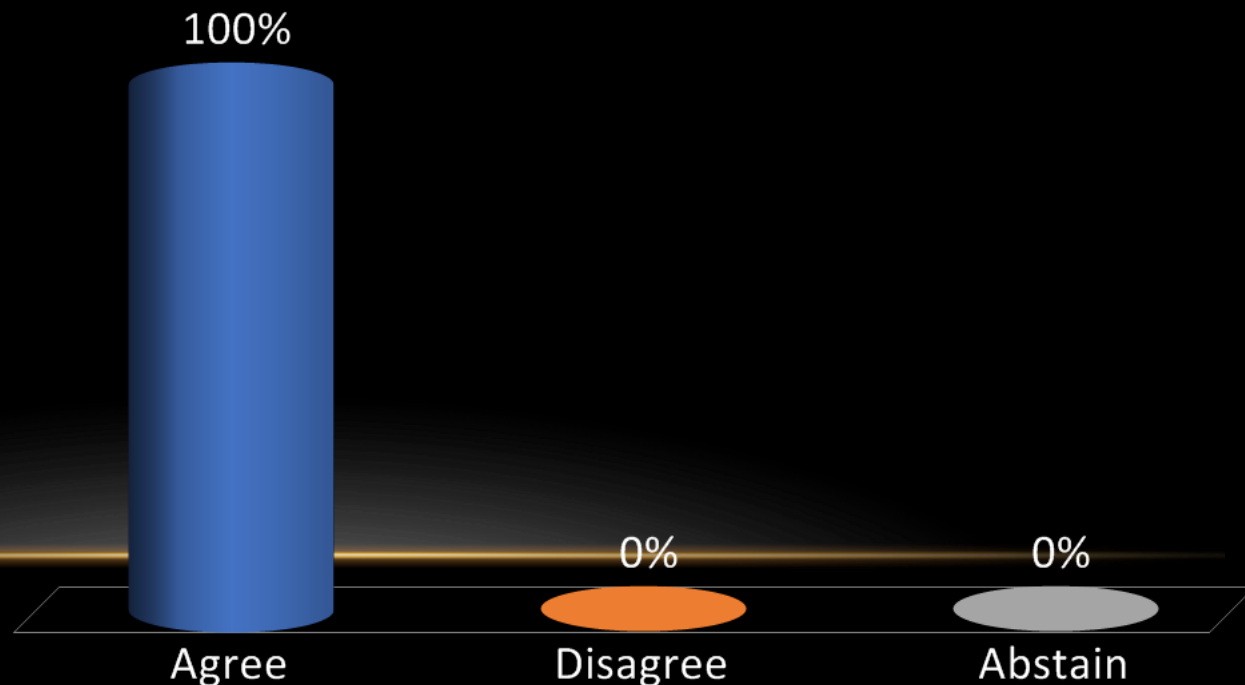


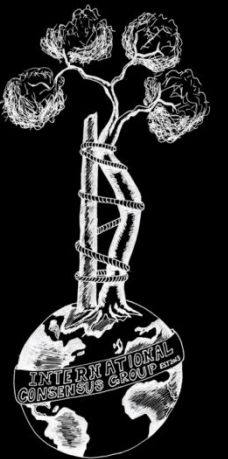
## Recommendation:

Unknown. There is no data that supports the best time delay between preoperative chemo/radiotherapy and a surgical tumor resection to minimize incidence of SSI/PJI. There are multiple intrinsic factors of each patient that can determine the best time to implant an endoprosthesis after a neoadjuvant treatment. Although no statistically significant association was seen between preoperative radiotherapy and surgical timing on wound complications (WC), trends suggest rates are lower if surgery is performed between 3 and 6 weeks following radiotherapy.

## Level of Evidence: Consensus

- A. Agree
- B. Disagree
- C. Abstain





**Onc-18 (Former Onc-31)** What strategies should be implemented to minimize the risk of SSI/PJI in patients who have received chemotherapy or radiation therapy and are undergoing endoprosthetic reconstruction?

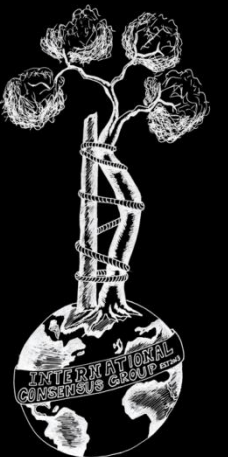
**RESEARCHED BY:**



Joao Fonseca de Freitas MD, Portugal

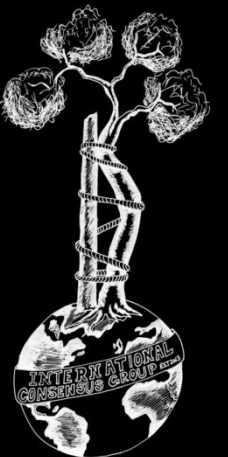


Arash Aalirezaie MD, Iran



# Literature:

- **Meta-analysis 3, Prospective/Randomized 1, Retrospective 17**
- Tumor patients undergoing endoprosthetic reconstruction and receiving chemo/radiotherapy are at an increased risk for infection. Any measure to minimize the risk of infection in this patient population needs to be implemented. We have proposed some preventative measures above but there is a desperate need for further studies to examine further measures.



## Recommendation:

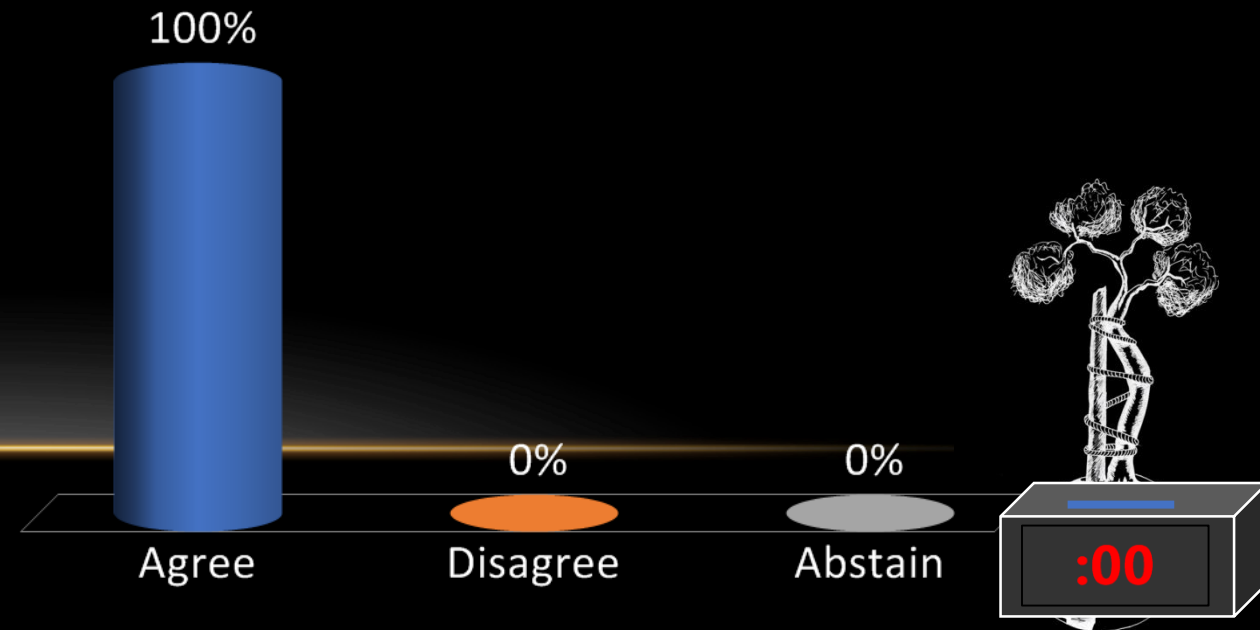
Patients who have received either chemotherapy or radiotherapy prior to endoprosthetic reconstruction should undergo appropriate medical optimization and receive appropriate perioperative antimicrobial prophylaxis.

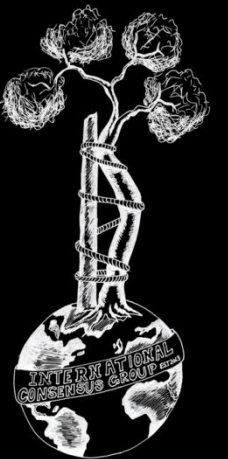
Other potential strategies include:

- use of antimicrobial coated implants
- adequate soft tissue reconstruction techniques
- expeditious surgery
- management at tertiary centers

## Level of Evidence: Limited

- A. Agree
- B. Disagree
- C. Abstain



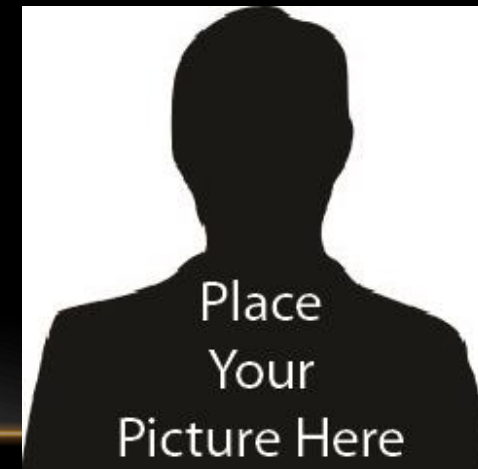

**Onc-19 (Former Onc-32)** What strategies, if any, should be used to minimize the risk of subsequent PJI/SSI in patients undergoing endoprosthetic reconstruction who are receiving or have received chemotherapy and/or radiation?

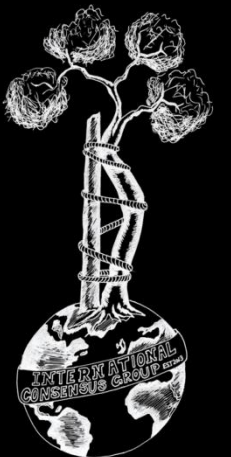
**RESEARCHED BY:**



John Abraham MD, USA

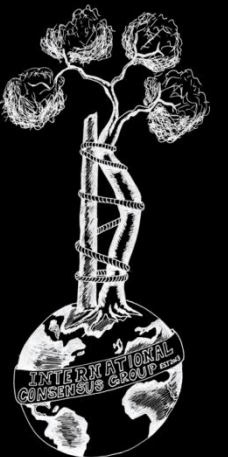


John Strony BS, USA



# Literature:

- **Meta-analysis 0, Prospective/Randomized 1, Retrospective 6**
- **Currently, there are no studies that directly answer this question.**

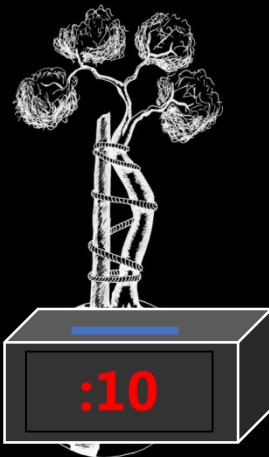
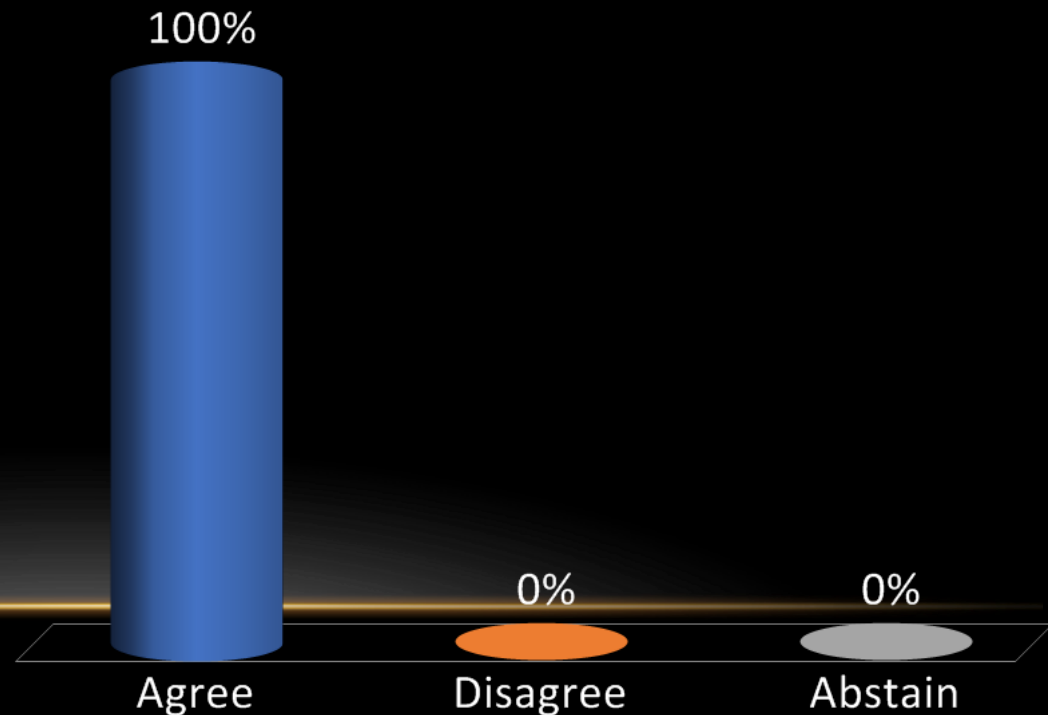


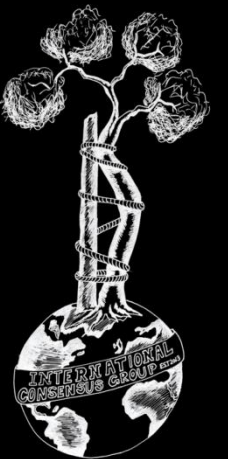
## Recommendation:

Unknown. No studies have investigated what strategies, if any, should be used to minimize the risk of subsequent PJI/SSI in patients undergoing endoprosthetic reconstruction who are or have received chemotherapy and/or radiation.

## Level of Evidence: Limited

- A. Agree
- B. Disagree
- C. Abstain



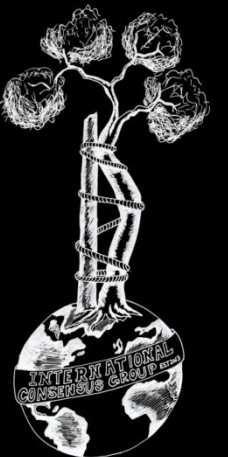


**Onc-20 (Former Onc-33)** What type, dose, and duration of prophylactic antibiotic(s) should be administered to patients undergoing oncologic endoprosthetic reconstruction who have received or will be receiving chemotherapy and/or radiation?

**RESEARCHED BY:**

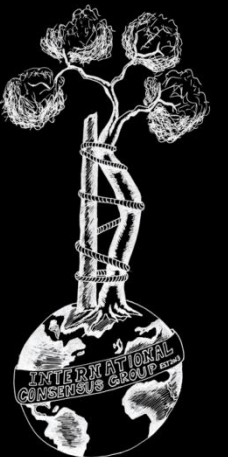


Mitchell Schwaber MD, Israel



# Literature:

- **Meta-analysis 1, Prospective/Randomized 2, Retrospective 5**
- No studies have been conducted addressing the tailoring of antibiotic prophylaxis in oncologic patients undergoing tumor surgery pre- or post-radiation or chemotherapy, including endoprosthetic reconstruction



## Recommendation:

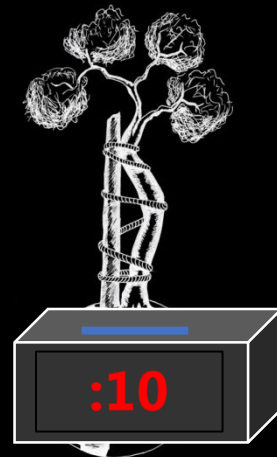
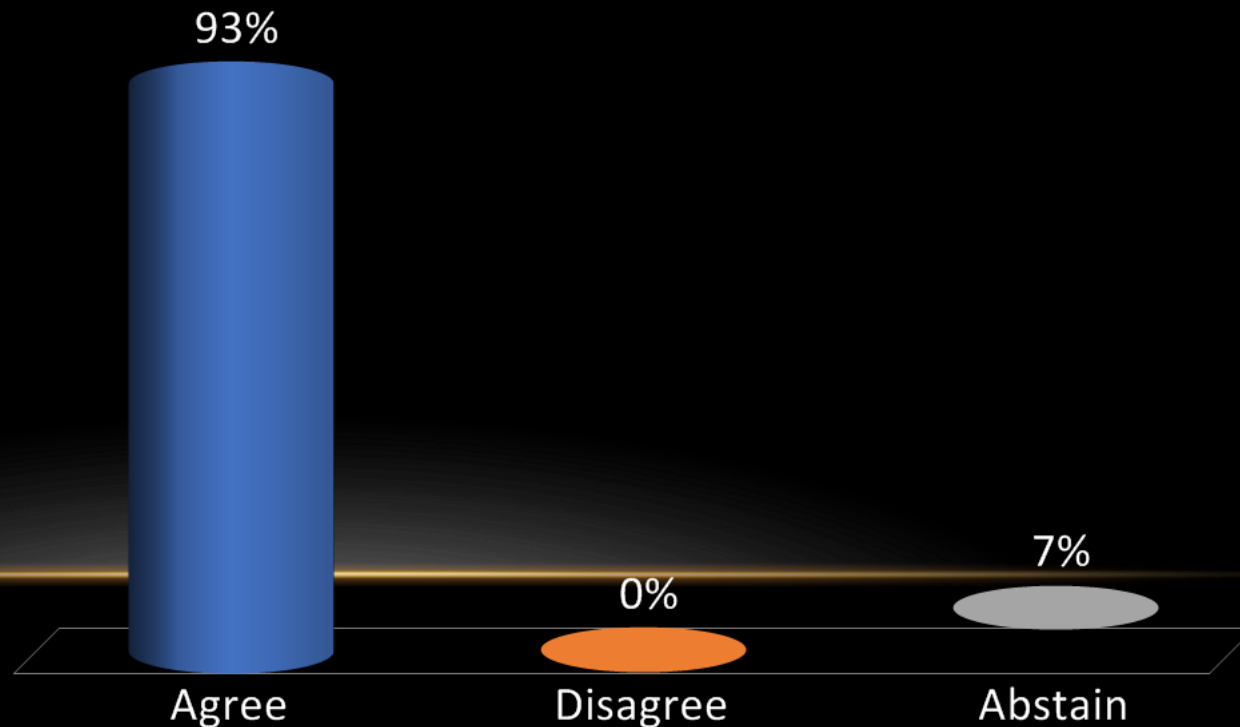
Evidence and guidelines directing the prescription of prophylactic antibiotic regimens in musculoskeletal tumor surgery are lacking.

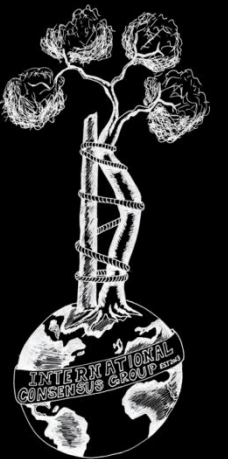
Antibiotic prophylaxis should be given consistent with existing guidelines for revision arthroplasty.

Although long-term antibiotic prophylaxis may decrease the risk of deep infection, there is currently no evidence to recommend its routine use, but studies are ongoing.

## Level of Evidence: Consensus

- A. Agree
- B. Disagree
- C. Abstain





**Onc-21 (Former Onc-34)** When should a surgical drain be removed to minimize the risk of subsequent SSI/PJI in patients who have received endoprosthetic reconstruction following resection of a musculoskeletal tumor?

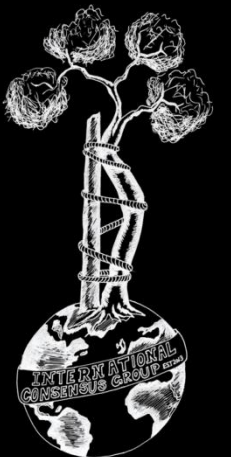
**RESEARCHED BY:**



Christina Gutowski MD, USA

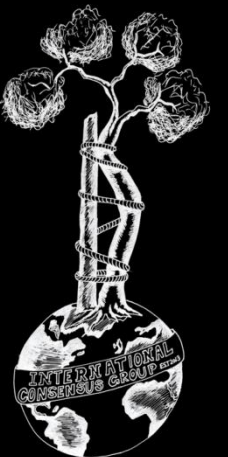


Michelle Ghert MD, Canada



# Literature:

- **Meta-analysis 4, Prospective/Randomized 4, Retrospective 13**
- From the arthroplasty and surgical literature, there is no evidence of benefit to extending antibiotic duration until drains are removed; however this has not specifically been evaluated in a musculoskeletal oncology patient population

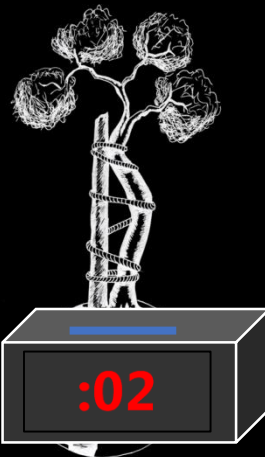
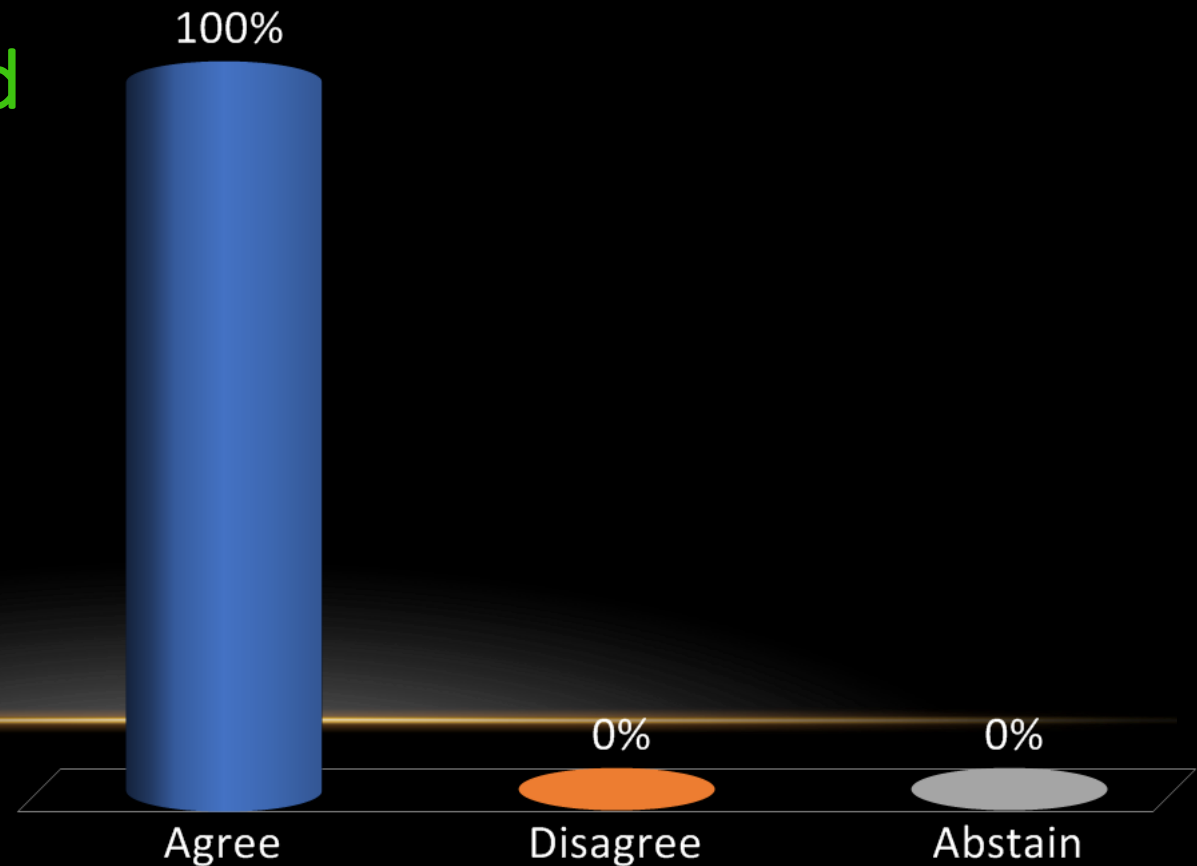


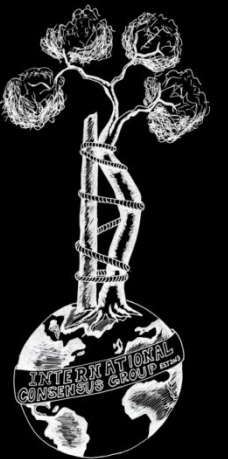
## Recommendation:

We recommend that the use and removal of surgical drains be individualized bearing in mind the potential for SSI increases with longer duration of drain in situ.

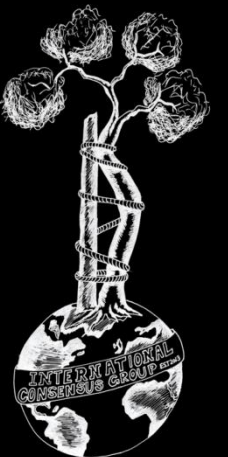
Level of Evidence: Limited

- A. Agree
- B. Disagree
- C. Abstain





# Treatment

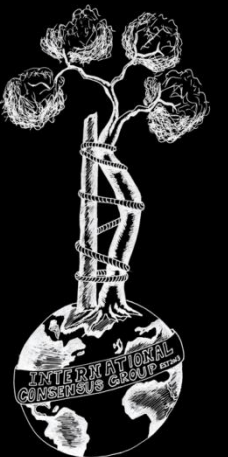


**Onc-22 (Former Onc-3)** Does the type, dose, and duration of antibiotic prophylaxis differ for patients undergoing oncologic endoprosthetic reconstruction compared to conventional TJA?

**RESEARCHED BY:**

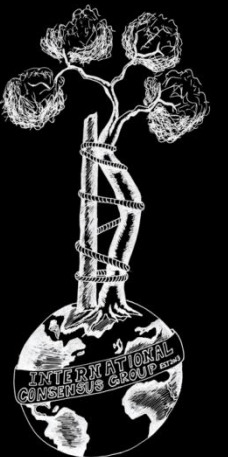


Mitchell Schwaber MD, Israel



# Literature:

- **Meta-analysis 2, Prospective/Randomized 0, Retrospective 4**
- **No data exists regarding tailoring of prophylaxis in oncologic patients with endoprosthetic reconstruction.**



## Recommendation:

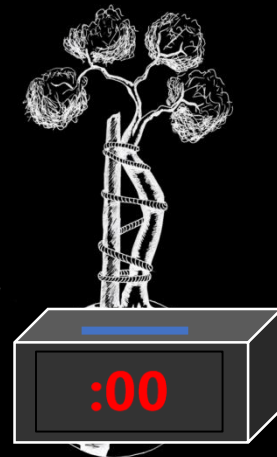
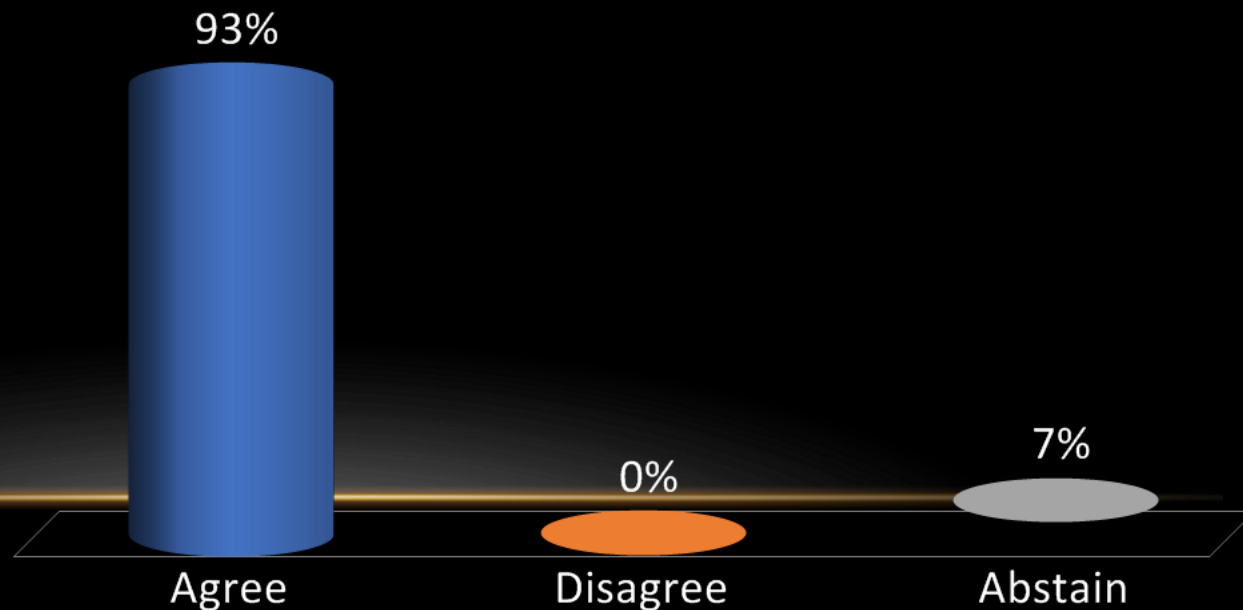
Evidence and guidelines directing the prescription of prophylactic antibiotic regimens in musculoskeletal tumor surgery are lacking.

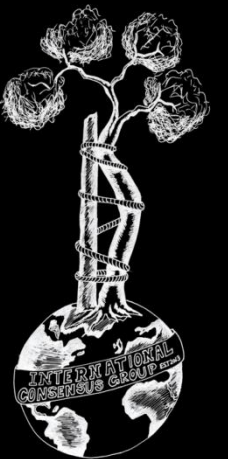
Antibiotic prophylaxis should be given consistent with existing guidelines for revision arthroplasty.

Although long-term antibiotic prophylaxis may decrease the risk of deep infection, there is currently no evidence to recommend its routine use, but there are ongoing studies.

## Level of Evidence: Consensus

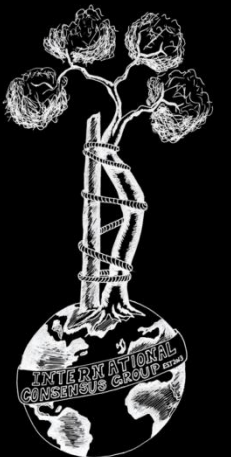
- A. Agree
- B. Disagree
- C. Abstain





# Onc-23 (Former Onc-5) Does the use of iodine-coated or silver-coated implants make one-stage exchange arthroplasty possible for management of patients with infected oncologic endoprosthesis?

## RESEARCHED BY:



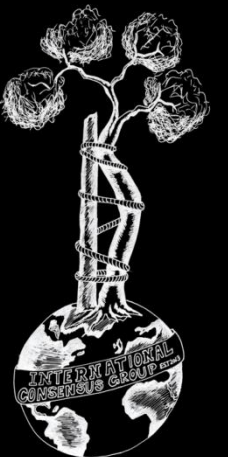
Michel van de Sande MD, Netherlands

Hiroyuki Tsuchiya MD, Japan

Daisuke Inoue MD, Japan

# Literature:

- **Meta-analysis 2, Prospective/Randomized 0, Retrospective 20**
- **There are a few studies in circulation that are promising and advocate for their success in one-stage revision surgery for eradicating infection. This investigative team believes that additional larger-scale investigations involving randomized control trials, prospective cohort and case-control studies are warranted.**

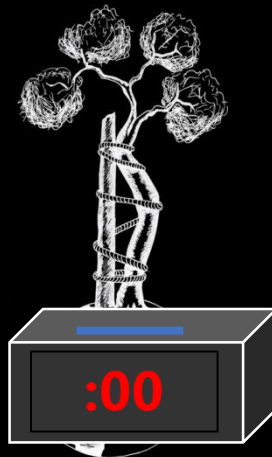
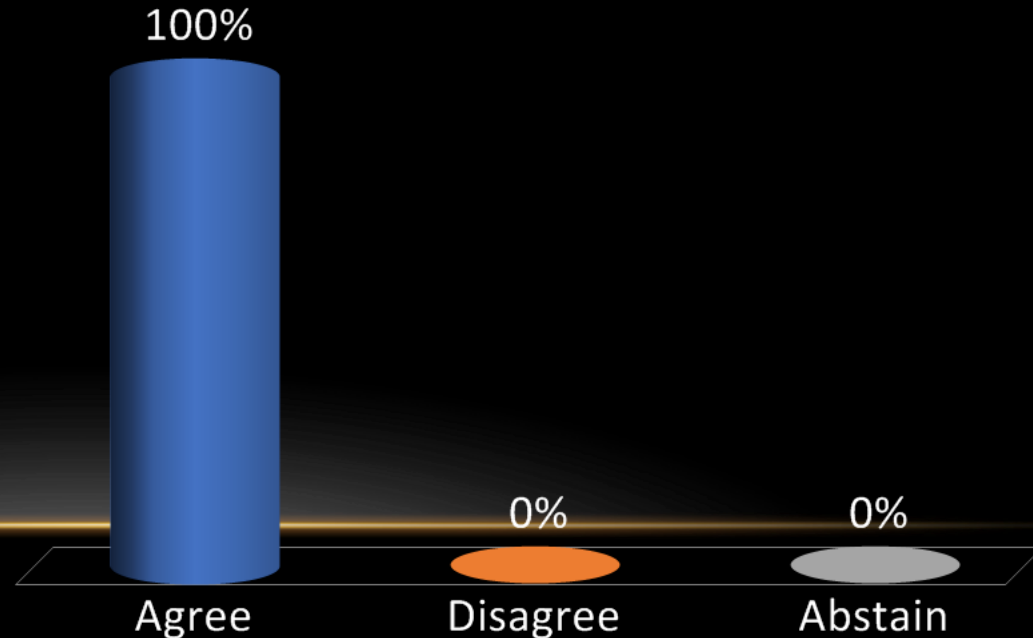


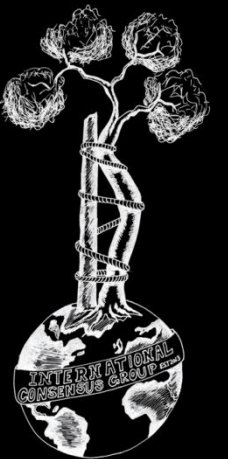
## Recommendation:

Unknown. Current literature has advocated the advantages of surface-modified coating (e.g., silver-coated, iodine-supported implants). Recently, there have been several retrospective, small-scale studies showing promising results for using surface-modified implants in one-stage exchange arthroplasty to treat infected oncologic endoprosthesis. However, to-date there is insufficient evidence to recommend this practice routinely.

## Level of Evidence: Limited

- A. Agree
- B. Disagree
- C. Abstain





**Onc-24 (Former Onc-7):** How many irrigation and debridement procedures of an infected oncologic endoprosthesis are reasonable before considering an alternative surgical management?

**RESEARCHED BY:**



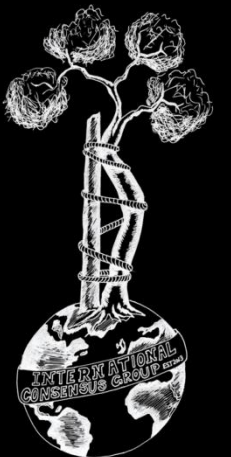
Oscar Ares MD, Spain



John Abraham MD, USA

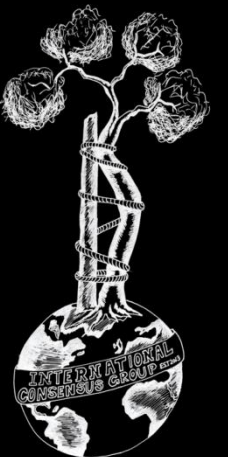


Joseph Benevenia MD, USA



# Literature:

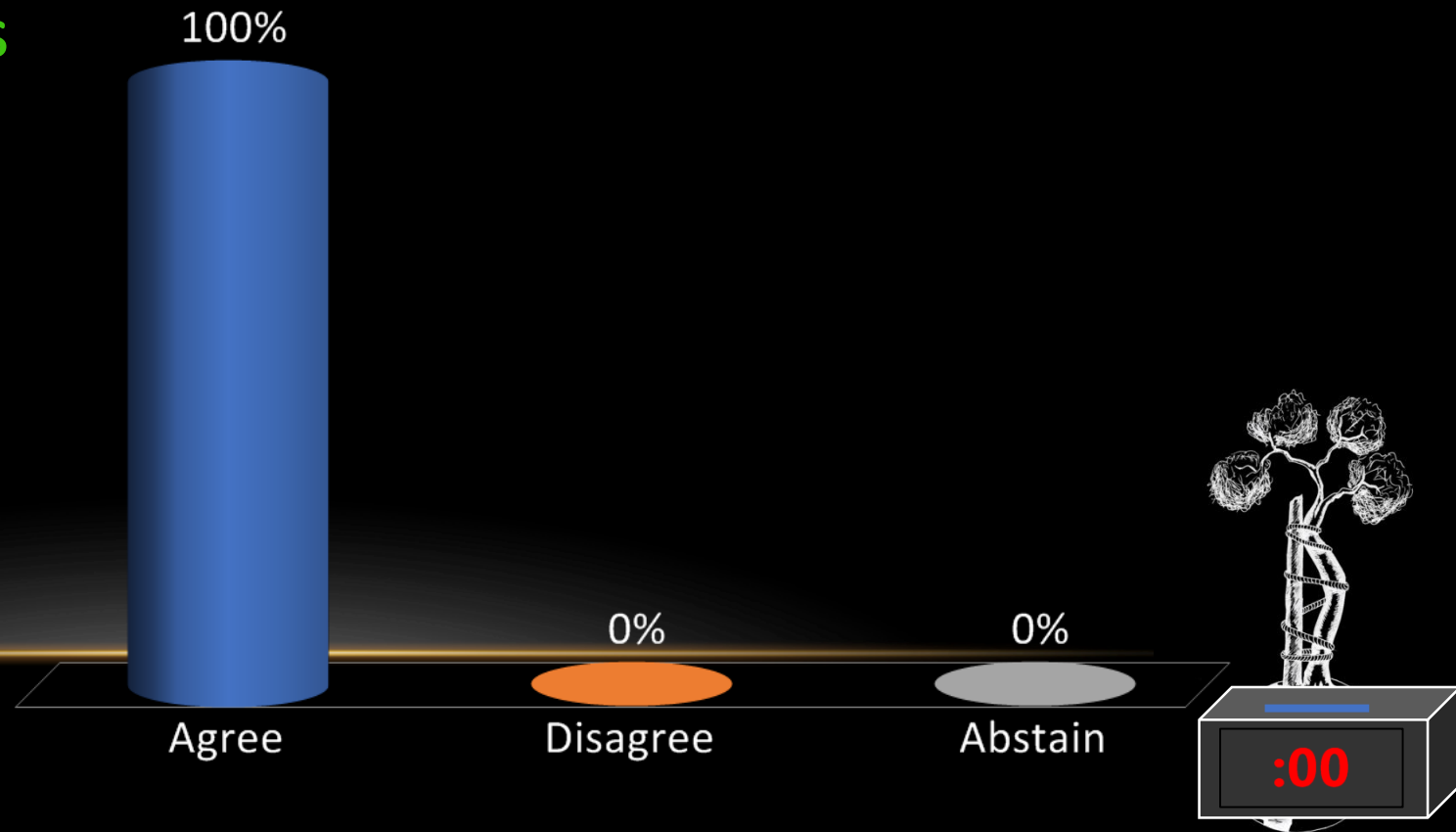
- **Meta-analysis 2, Prospective/Randomized 0, Retrospective 8**
- **Moderate evidence suggesting that for acute infections with an antibiotic – sensitive microorganism, debridement may be a good first step in the treatment algorithm, but failure rates are high, and no more than one surgical debridement should be attempted before considering a revision surgery in order to achieve infection eradication.**

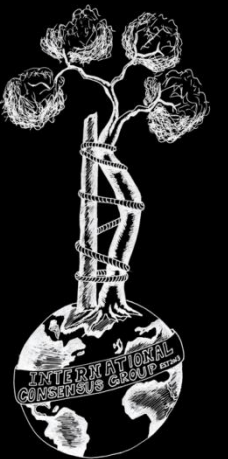


**Recommendation:** Decision to repeat irrigation and debridement and retention of an infected endoprosthesis (DAIR) should be made based on comorbidities of the host, virulence of the organism, complexity of the reconstruction, and status of the soft tissues. We believe DAIR performed more than three times is unlikely to be successful in curing infection.

**Level of Evidence: Consensus**

- A. Agree
- B. Disagree
- C. Abstain





# Onc-25 (Former Onc-8): How should acute reinfection of an oncologic endoprosthesis be treated?

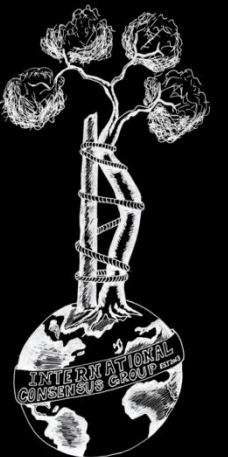
## RESEARCHED BY:



João Fonseca de Freitas MD, Portugal

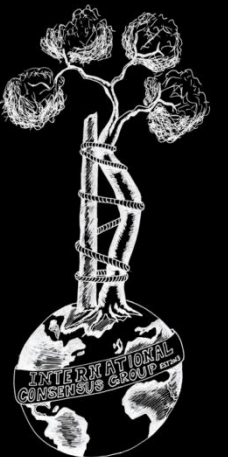


Scot A. Brown MD, USA



# Literature:

- **Meta-analysis 2, Prospective/Randomized 0, Retrospective 46**
- **Strong evidence suggesting careful planning, consideration of the patient's prognosis, and a potentially aggressive surgical approach to manage infections after reconstructive surgery for bone tumors.**

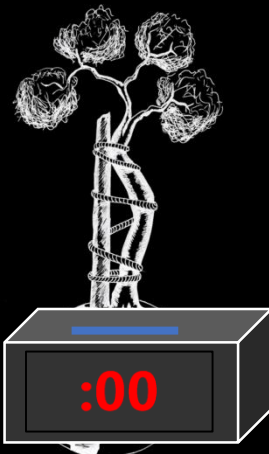
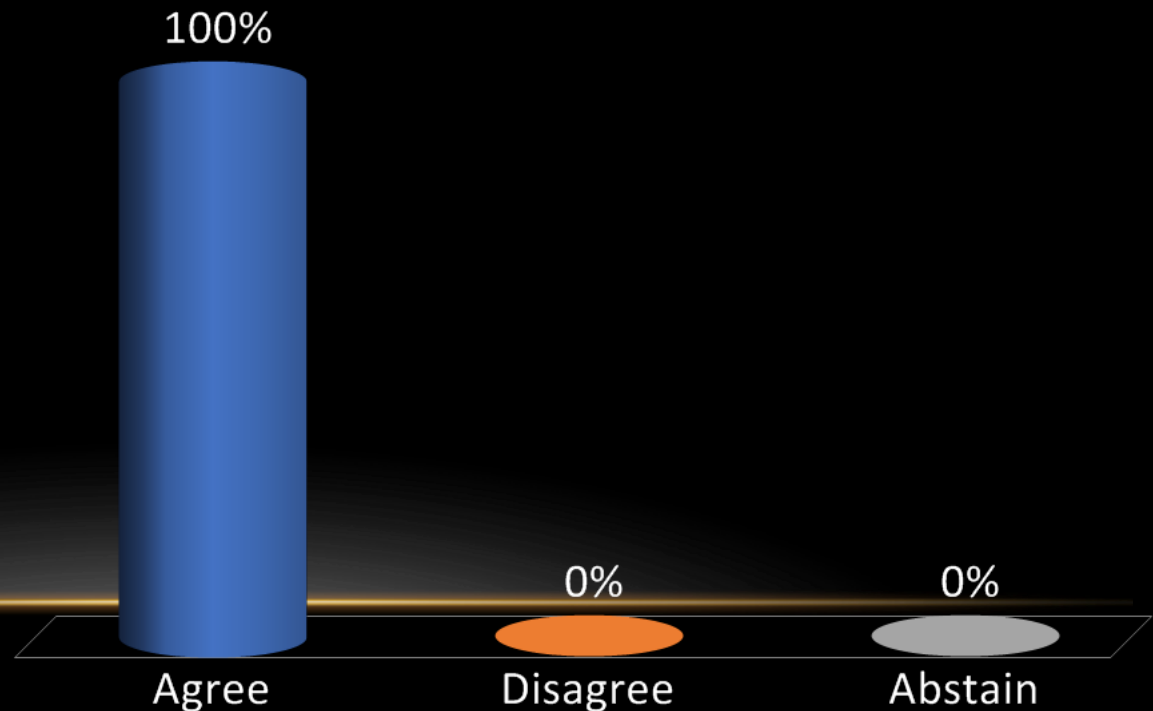


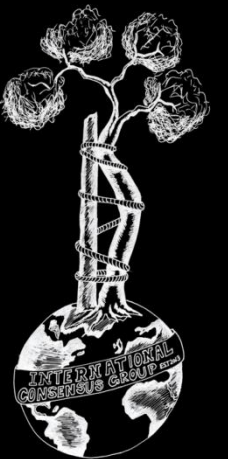
## Recommendation:

- Acute reinfections in patients with oncologic endoprostheses demand treatment with multi-disciplinary treatment input.
- The most appropriate treatment modality for acute re-infection will depend on the host, the organism, and the soft tissue quality. A DAIR is a frequently employed strategy. However, a one-stage, two-stage, or partial-exchange are reasonable.

## Level of Evidence: Consensus

- A. Agree
- B. Disagree
- C. Abstain





**Onc-26 (Former Onc-9):** Is irrigation and debridement, and exchange of modular parts, a viable option for treatment of acute PJI involving oncologic endoprosthesis? If so, what are the indications?

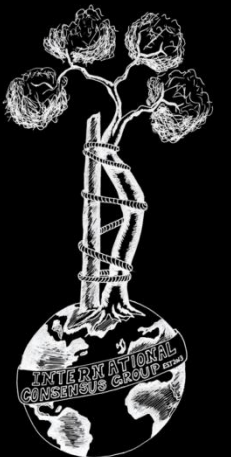
**RESEARCHED BY:**



Paul Jutte MD, Netherlands

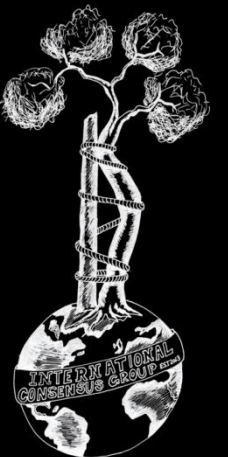


Hesham Abdelbary MD, Canada



# Literature:

- **Meta-analysis 4, Prospective/Randomized 11, Retrospective 70**
- **Moderate evidence due to lack of strong levels of evidence published in the form of meta-analyses or randomized controlled trials.**

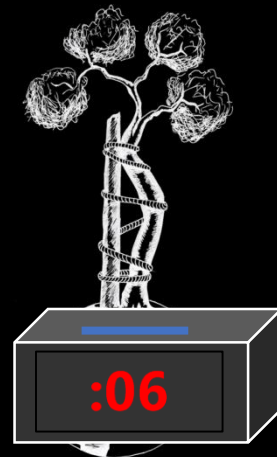
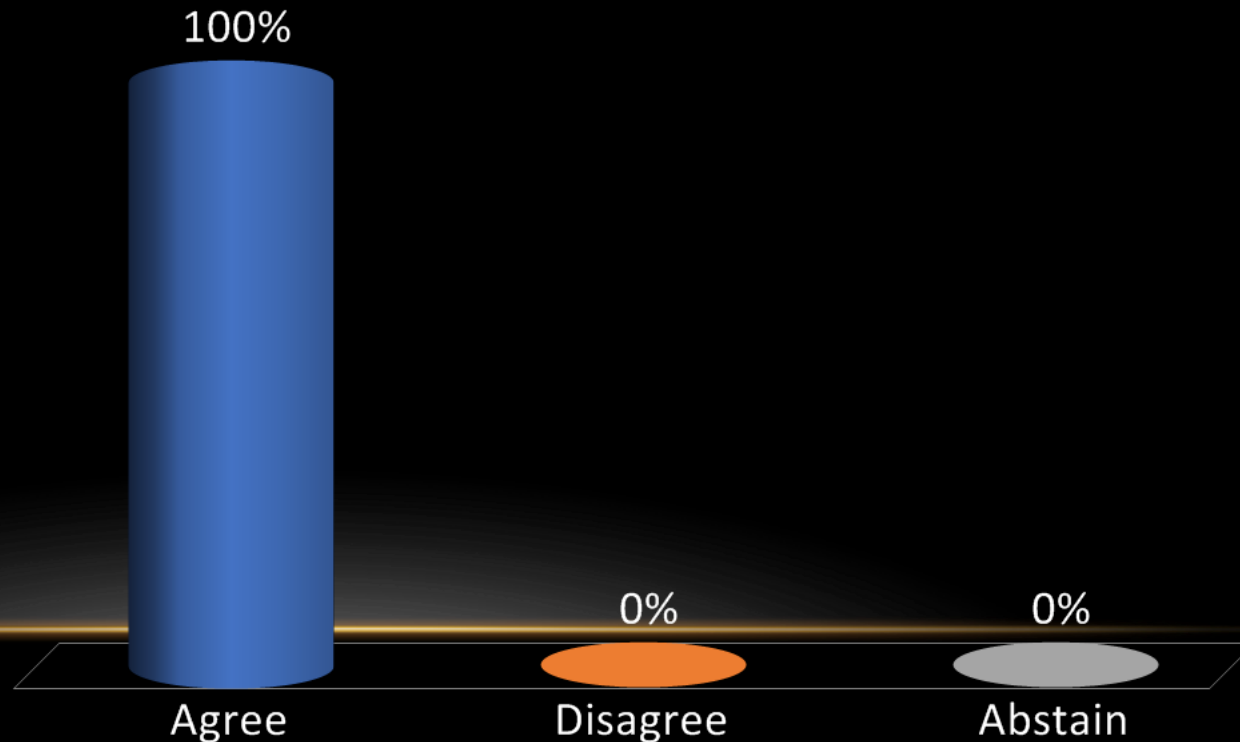


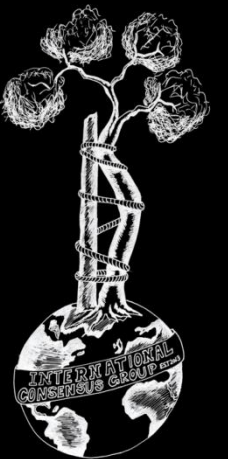
## Recommendation:

- Yes. Irrigation and debridement with retention of prosthesis (DAIR) is a viable option for management of patients with infected endoprosthesis.
- The procedure may be offered to patients with early infection (<3 months), short duration of symptoms (<3 weeks), well-fixed implants and well-characterized, highly susceptible pathogen.

Level of Evidence: Moderate

- A. Agree
- B. Disagree
- C. Abstain





# Onc-27 (Former Onc-11): Is there a role for single stage exchange arthroplasty for patients with infected oncologic endoprosthesis?

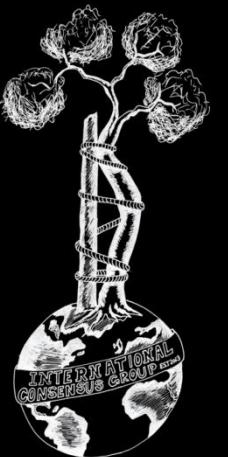
## RESEARCHED BY:



Michelle Ghert MD, Canada

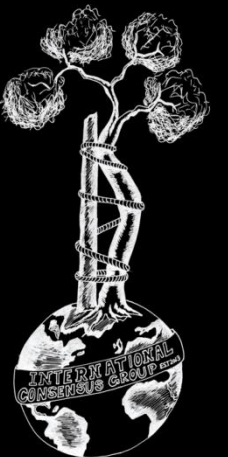


Roberto Velez MD, Spain



# Literature:

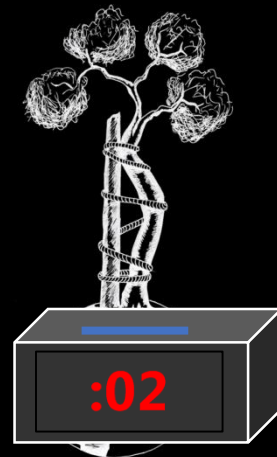
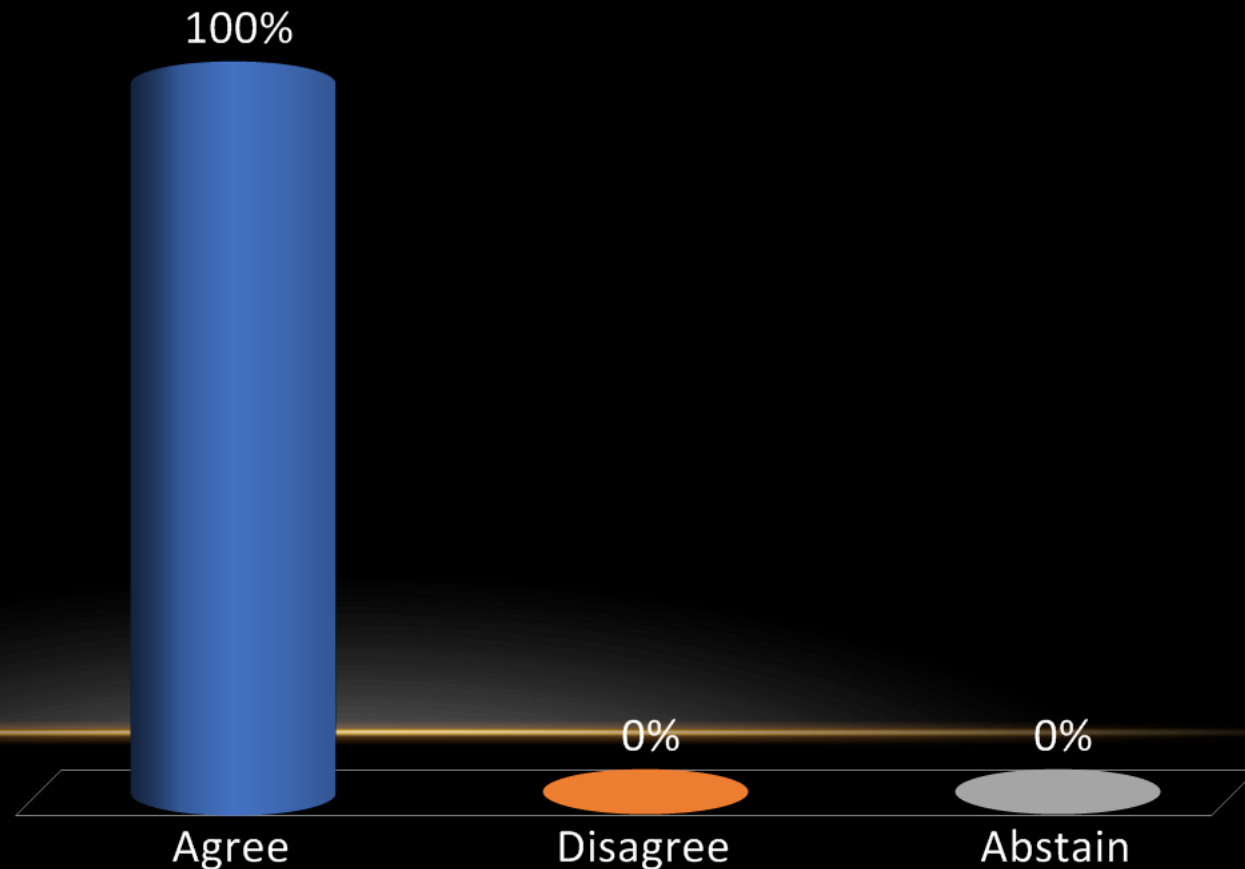
- **Meta-analysis 0, Prospective/Randomized 0, Retrospective 9**
- **Limited evidence - Future research is needed to determine which group of patients would most benefit from one stage exchange arthroplasty versus two stage exchange arthroplasty that happens to be the preferred method of treatment of chronic PJI in hip and knee arthroplasty.**

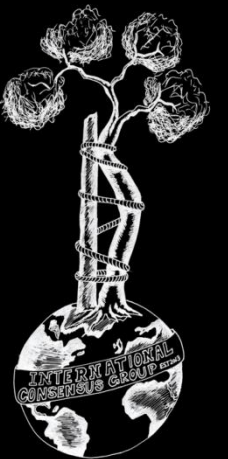


**Recommendation:** Yes, there is a role for single-stage exchange arthroplasty in selected patients. There is limited evidence for the successful use of single-stage exchange in infected oncologic endoprosthesis.

**Level of Evidence:** Limited

- A. Agree
- B. Disagree
- C. Abstain





**Onc-28 (Former Onc-20):** Should the management of PJI involving an oncologic endoprosthesis differ from that of conventional joint replacement prostheses?

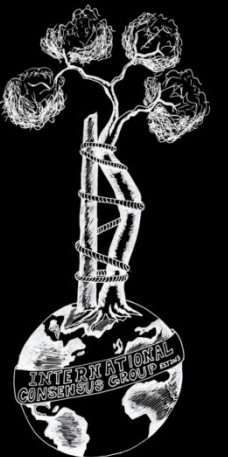
**RESEARCHED BY:**



Germán Luis Farfalli MD, Argentina

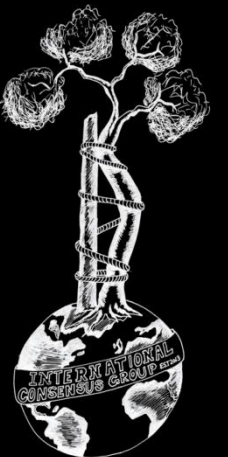


Peter Choong MD, Australia



# Literature:

- **Meta-analysis 0, Prospective/Randomized 0, Retrospective 14**
- **Limited evidence - There is no consensus in the management of an infected endoprosthesis given the limited data. The current recommendation is based on treatment of infected primary arthroplasties.**

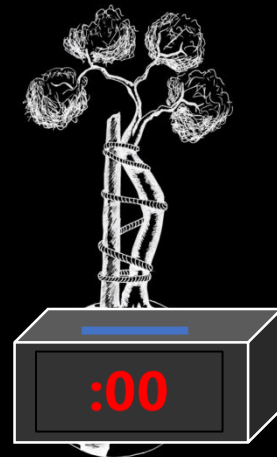
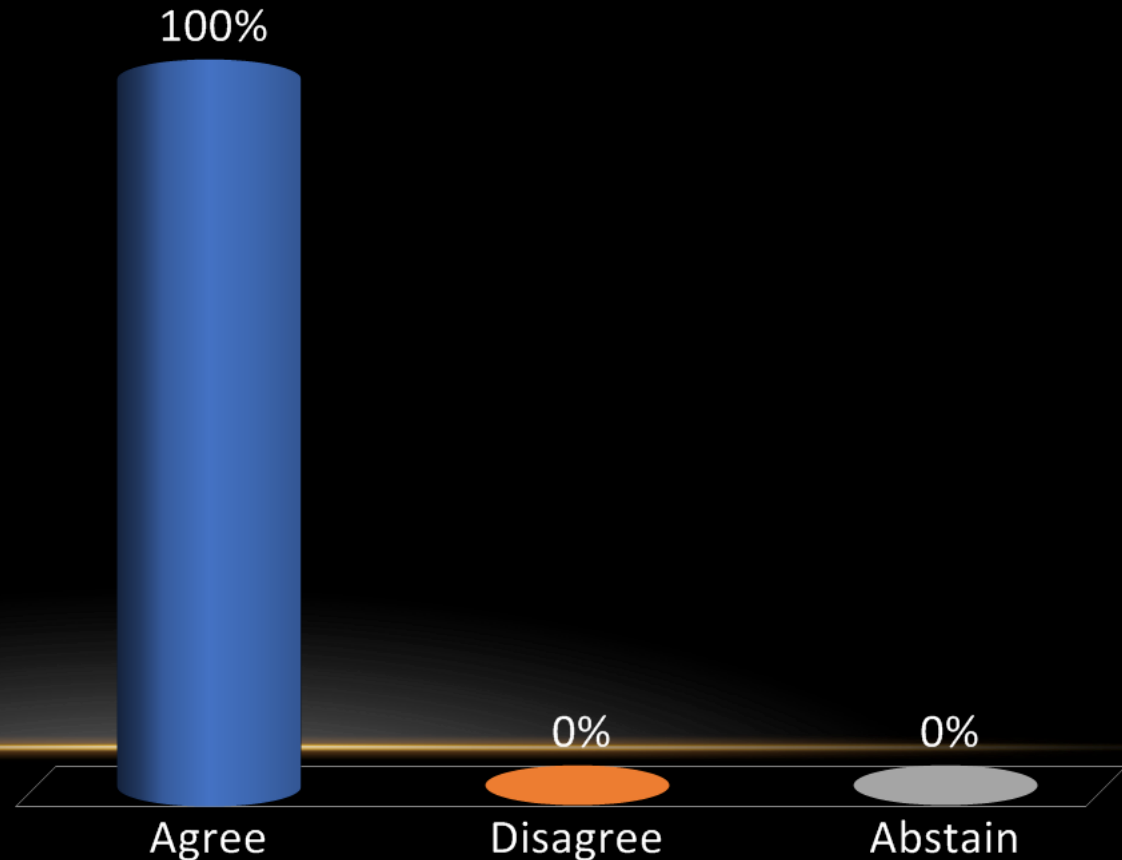


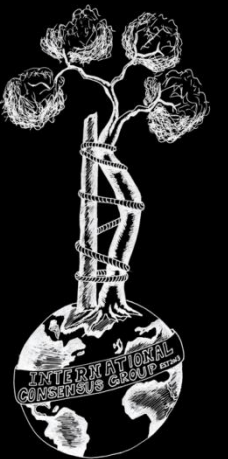
## Recommendation:

- No. The management of PJI involving an oncologic endoprosthesis is similar to that of conventional joint replacement prosthesis.

Level of Evidence: Limited

- A. Agree
- B. Disagree
- C. Abstain





**Onc-29 (Former Onc-24):** What factors may improve the outcome of a two-stage exchange arthroplasty in patients with an infected oncologic endoprosthesis?

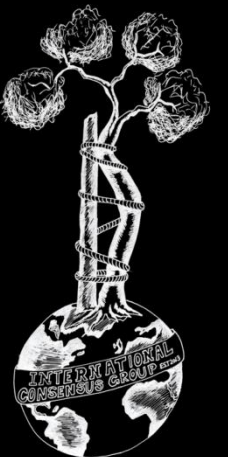
**RESEARCHED BY:**



Paul Jutte MD, Netherlands

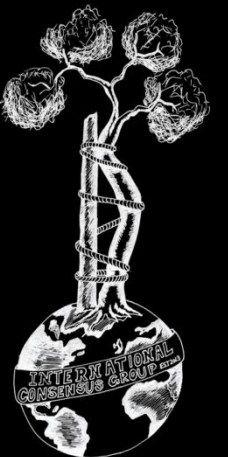


Hesham Abdelbary MD, Canada



# Literature:

- **Meta-analysis 1, Prospective/Randomized 10, Retrospective 34**
- **Limited evidence – There are no studies directly answering this question.**



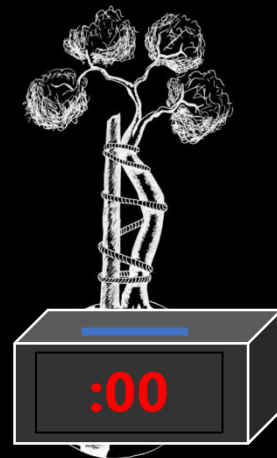
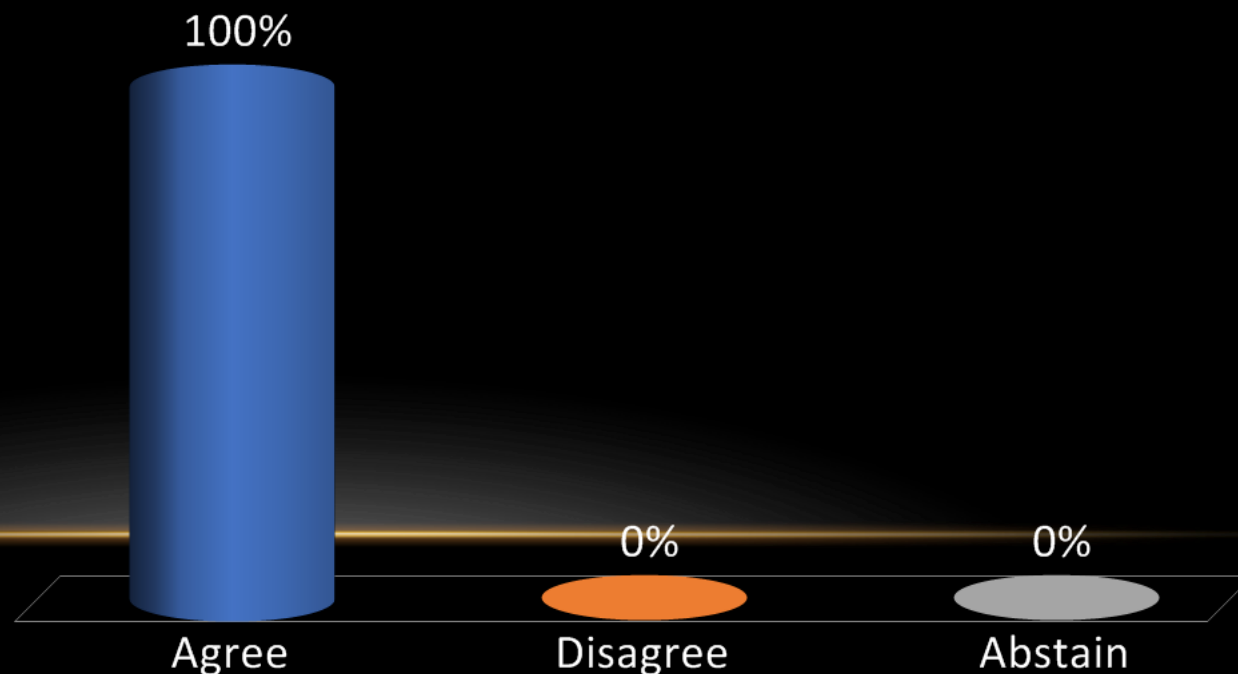
## Recommendation:

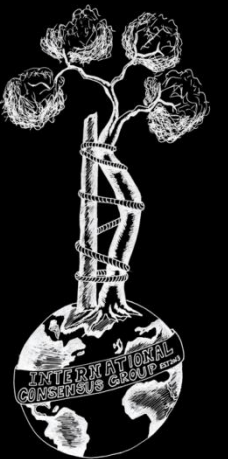
There are numerous factors that improve the outcome of two-stage exchange arthroplasty in general, and after oncologic reconstruction in particular, which include:

- Host related factors (such as host optimization by treating anaemia, malnutrition, hyperglycemia, immunosuppressive state, etc).
- Organism related factors (such as administration of appropriate systemic and local antibiotics)
- Surgery related factors (such as aggressive debridement of soft tissue and bone, optimal soft tissue management, local delivery of antimicrobial agents, surface modified implants, and prevention of postoperative complications).

## Level of Evidence: Limited

- A. Agree
- B. Disagree
- C. Abstain





# Onc-30 (Former Onc-26): What is the best reconstruction technique for an infected allograft?

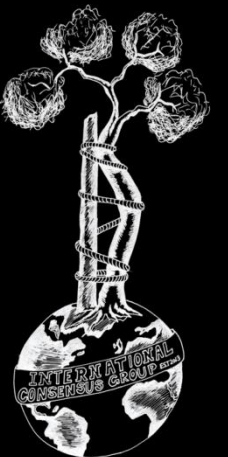
## RESEARCHED BY:



Muhammad Ather Siddiqi MD, Pakistan

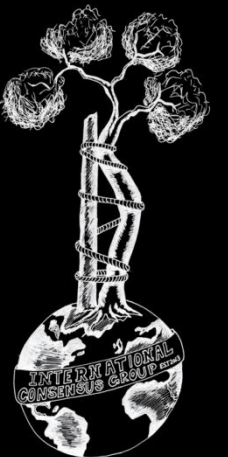


A. Mazhar Tokgözoğlu MD, Turkey



# Literature:

- **Meta-analysis 1, Prospective/Randomized 0, Retrospective 8**
- **Moderate evidence – Current data is inconclusive so there is a need for higher quality studies.**

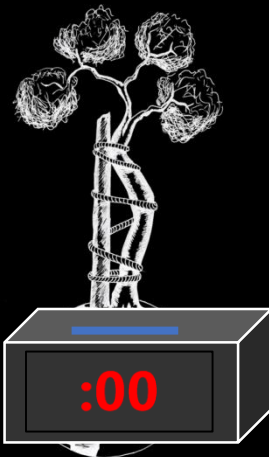
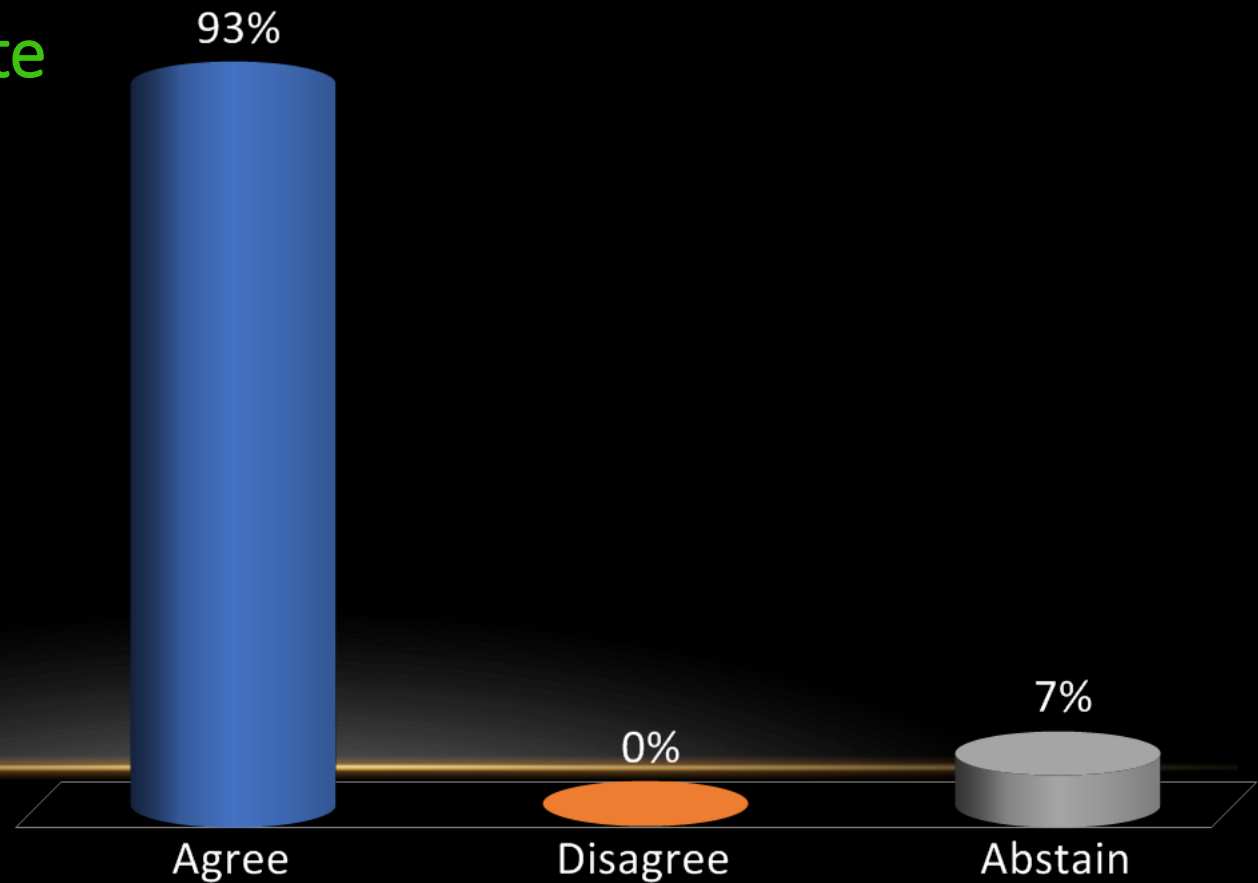


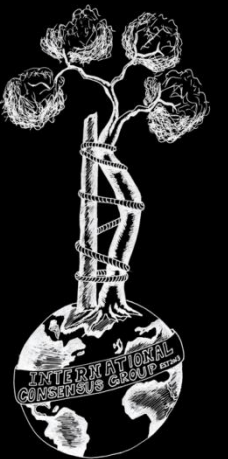
## Recommendation:

- The best reconstruction an infected allograft is resection of the infected allograft and a biologic and/or prosthetic reconstruction.

Level of Evidence: Moderate

- A. Agree
- B. Disagree
- C. Abstain





**Onc-31 (Former Onc-27):** What is the best surgical treatment for management of a chronically infected oncologic endoprosthesis? Does this change if the patient is receiving or has received recent chemotherapy and/or irradiation?

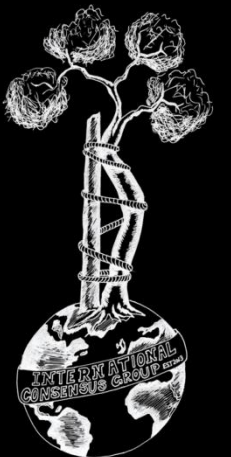
**RESEARCHED BY:**



John Abraham MD, USA

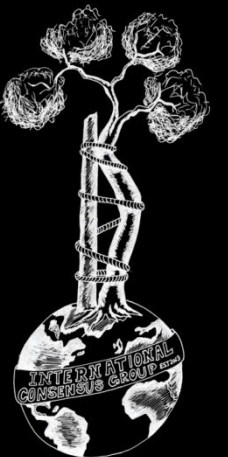


Joseph Benevenia MD, USA



# Literature:

- **Meta-analysis 0, Prospective/Randomized 0, Retrospective 5**
- **Limited evidence suggesting that two-stage revision is currently more supported by literature as a surgical treatment for the management of a chronically infected oncologic endoprosthesis. However, due to the presence of some conflicting data, the strength of this recommendation is limited.**

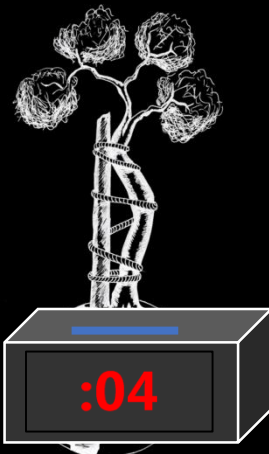
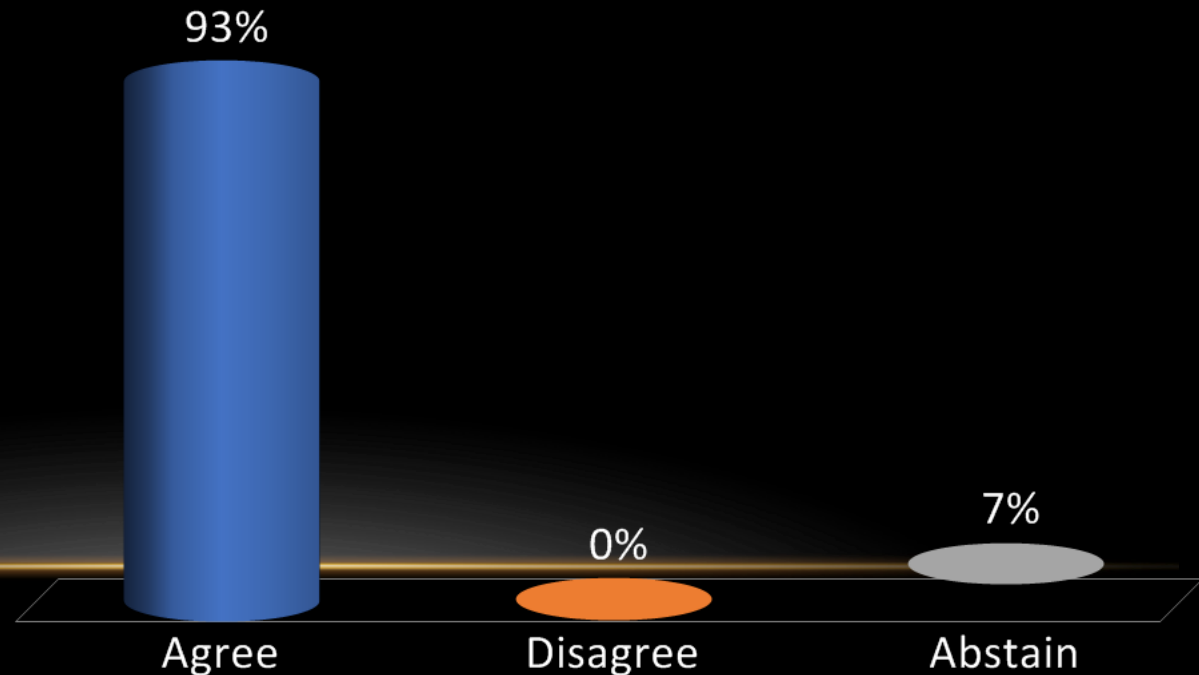


## Recommendation:

- We recommend a two-stage revision in the management of a chronically infected oncologic endoprosthesis, however, acknowledge that a one-stage exchange is also a viable option.
- There is no study to suggest that this recommendation should change if the patient is receiving or has received recent chemotherapy and/or irradiation.
- The patient's oncologic prognosis may favor performing DAIR procedure with adjunct antibiotic suppression, amputation, or arthrodesis.

## Level of Evidence: Limited

- A. Agree
- B. Disagree
- C. Abstain



The End  
Thank you!

